Shoulder Pain:
How to Make the Diagnosis

By
Mary Lloyd Ireland, M.D.

Objectives

- Develop concepts of correlation anatomy, injury mechanism, PE and imaging to make correct diagnosis
- Show case-based examples of shoulder disorders
- Understand making the correct primary diagnosis will improve patient outcomes and management of shoulder pain patients

Comprehensive Shoulder Exam
MAIN MENU

QUIT

Differential Diagnosis

Think Joint		Mechanism
Joints (3)	Glenohumeral	One Event
	SC	
	AC	
Spaces (2)	Subacromial	Repetitive
	Scapulothoracic	
Referred	Neck	Repetitive - No event
	Scapula	
	Lung	
	Ribs	

FUNCTIONAL ANATOMY: Joints

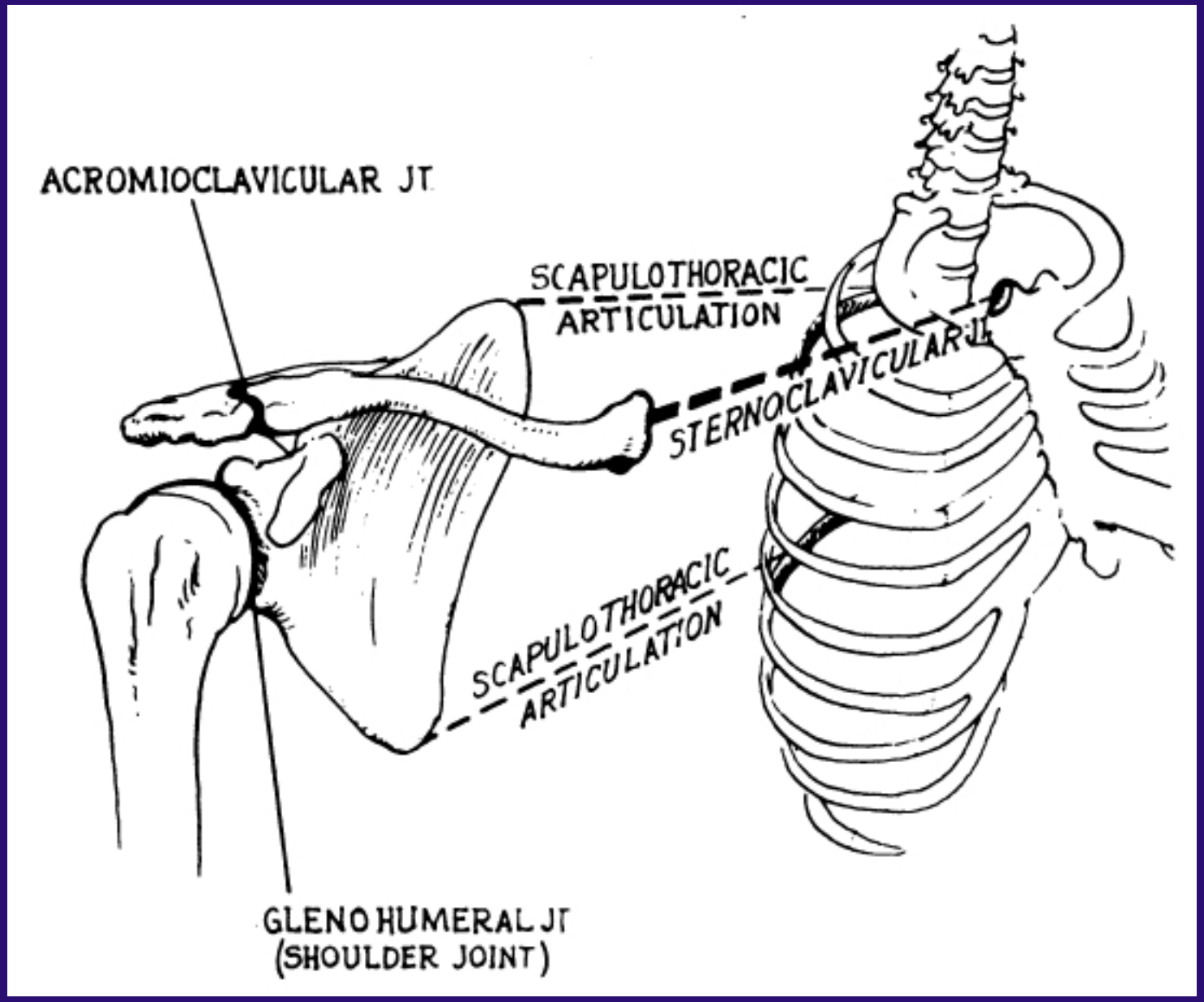

Primary Diagnosis

- Involved Structure
- Age Group
  - Younger Instability (<30 yrs)
  - Older Rotator cuff (>40 yrs)
- Diagnosis
  - Inflammation
  - Tear
  - Sprain
  - Instability

Elevation/Depression of the Scapula

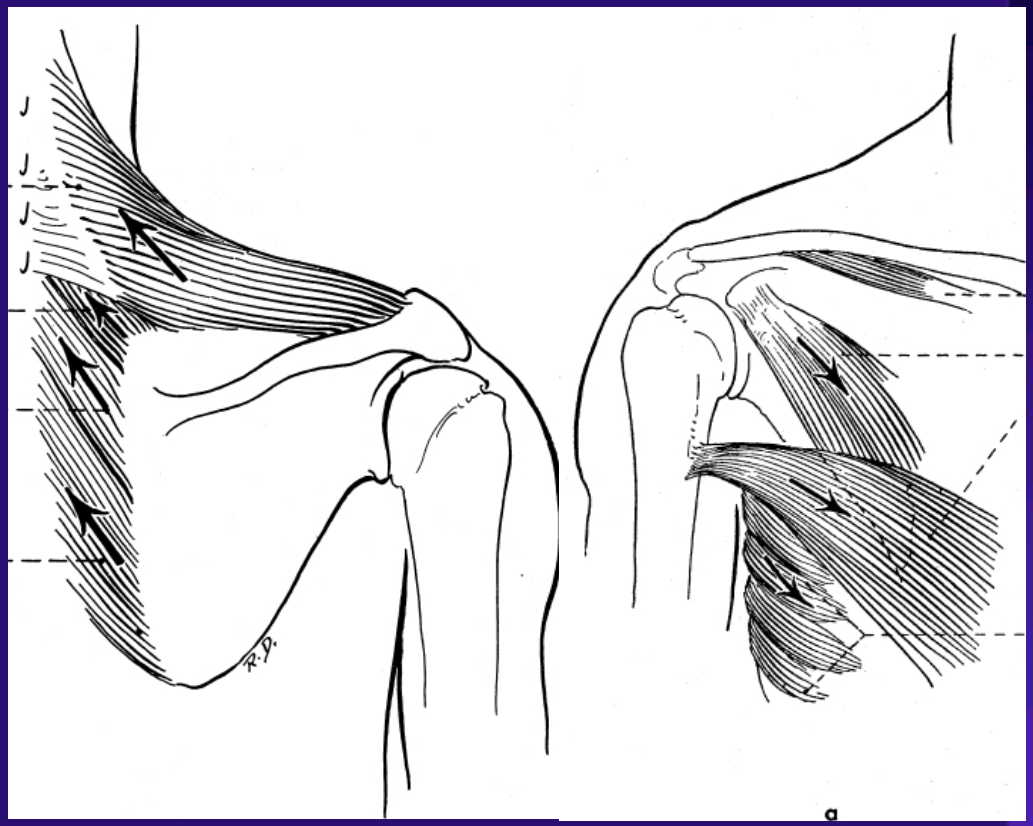

Upward/Downward Rotation of the Scapula

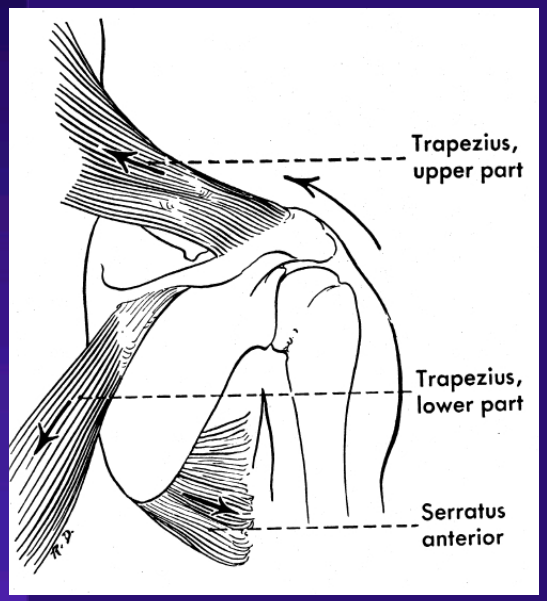

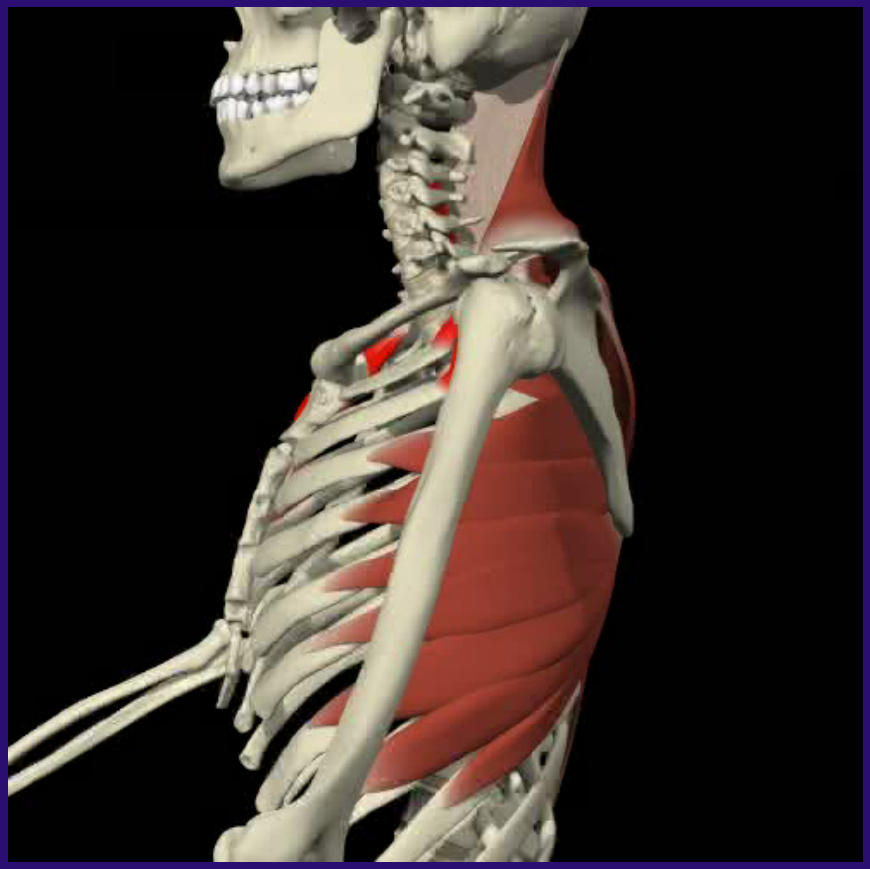

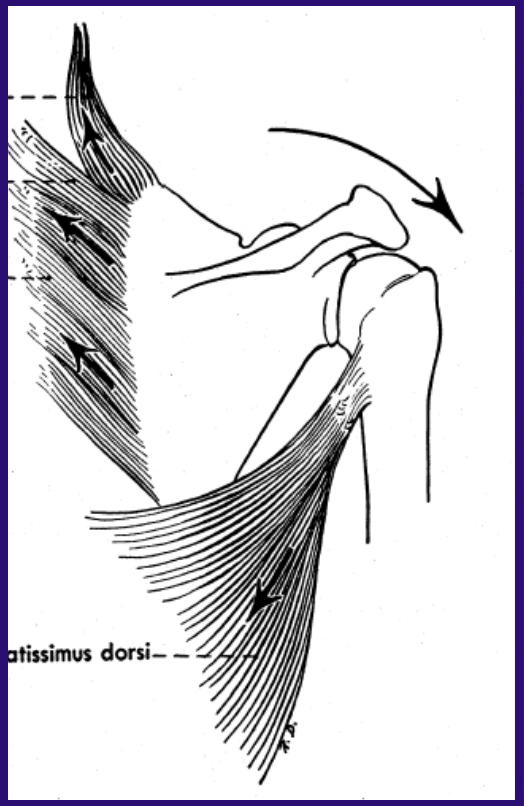

Musculature: Protractors and Retractors of the Scapula

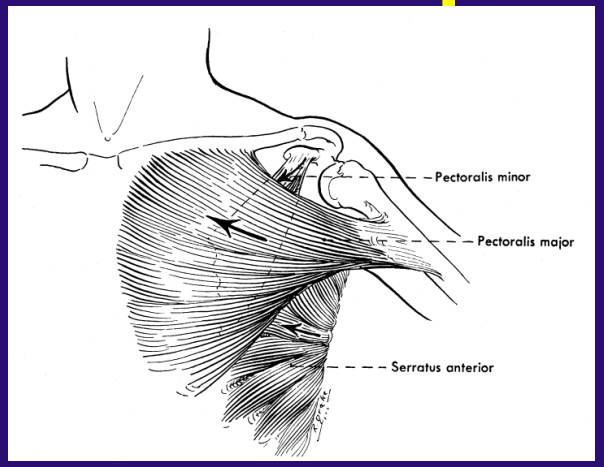

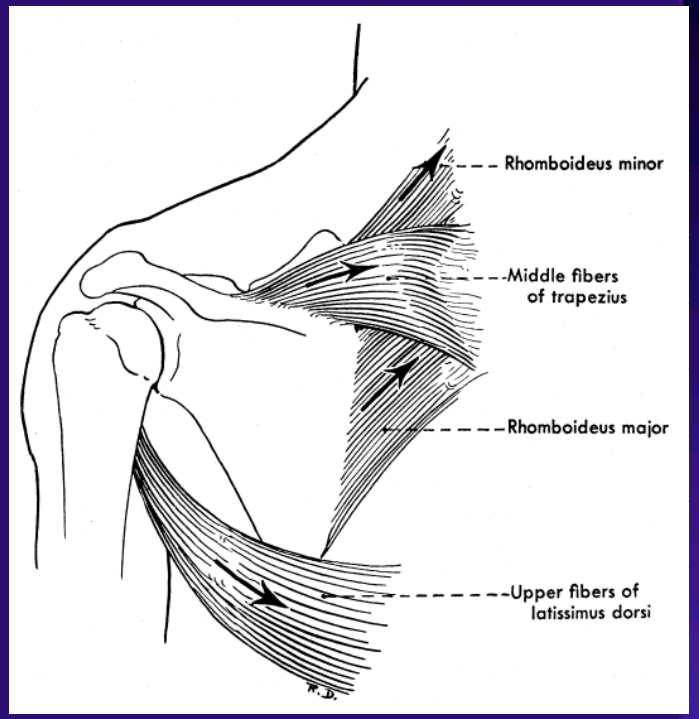

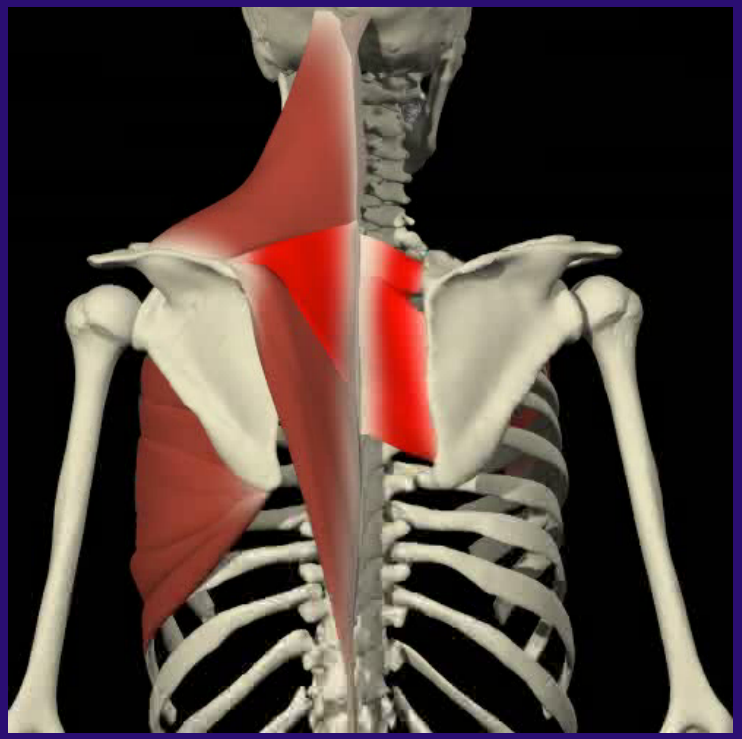

Abduction/Adduction of the Shoulder

Flexion/Extension of the Shoulder

Scapular Winging

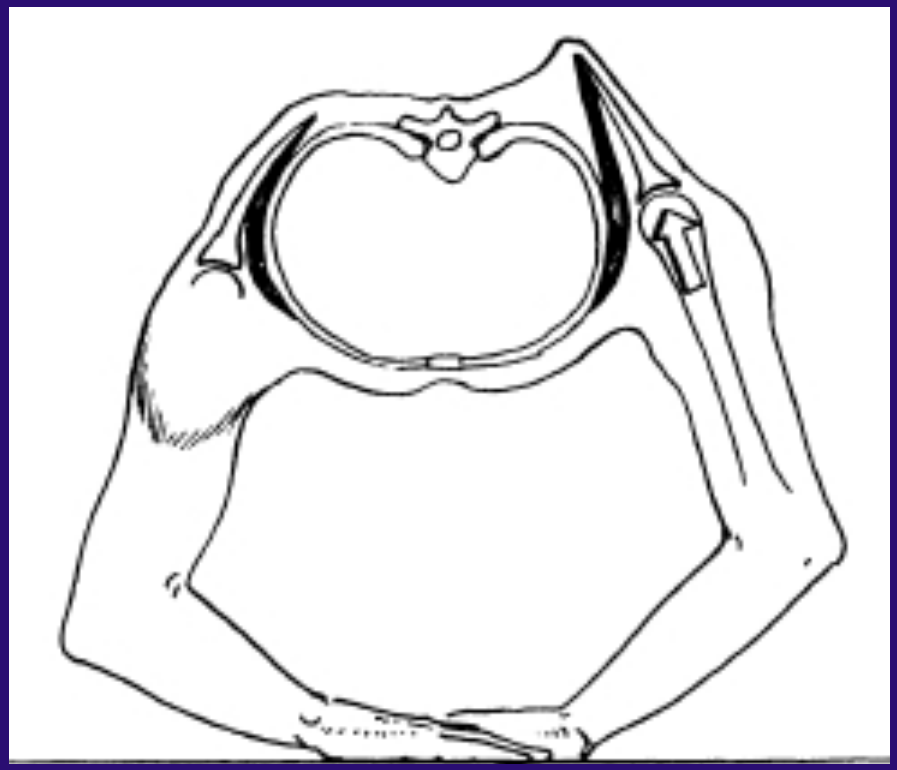

Scapular winging indicates weakness of the serratus anterior muscle and is evident when the patient does a push-up or pushes agains the wall.

Remember to examine scapular position

- Have patient reproduce symptoms
- If scapula is unstable, shoulder problems will result
- An unstable scapula is similar to firing a cannon out of a canoe

Scapular Dysfunction

- If exists, shoulder function is like *firing a cannon out of a canoe!*
- Remember the scapula!
  - Tightness anterior
  - Forward head
  - Overdeveloped pectoralis
    - Scapular movements
  - Touch medial borders
  - Elbows to back pocket
  - Shrugs
  - Clockwise/counterclockwise

Scapular Winging

Like firing a cannon out of a canoe . . .

Is the pain referred?

- Neck
- Scapula
- Lung
- Ribs
- Tumor

Neurologic stretch injury from lifting heavy dumbbells, suprascapular (C5) nerve involved

Muscle Testing

Table 39-1. Shoulder Muscle Testing Chart

MUSCLE	INNERVATION	MYOTOMES	TECHNIQUE FOR TESTING
Trapezius	Spinal accessory	C2–C4	Patient shrugs shoulders against resistance.
Sternomastoid	Spinal accessory	C2–C4	Patient turns head to one side with resistance over opposite temporal area.
Serratus anterior	Long thoracic	C5–C7	Patient pushes against wall with outstretched arm. Scapular winging is observed.
Latissimus dorsi	Thoracodorsal	C7–C8	Downward backward pressure of arm against resistance. Muscle palpable at Inf. angle of scapula during cough.
Rhomboids	Dorsal	(C4) C5[a]	Hands on hips pushing elbows backward against resistance.
Levator scapulae	Scapular		
Subclavius	Nerve to subclavius	C5–C6	None
Teres major	Subscapular (lower)	C5–C6	Similar to lat. dorsi; muscle palpable at lower border of scapula.
Deltoid	Axillary	C5–C6 (C7)	With arm abducted 90°, downward pressure is applied. Anterior and posterior fibers may be tested in slight flexion and extension.
Subscapularis	Subscapular (upper)	C5	Arm at side with elbow flexed to 90°. Examiner resists internal rotation.
Supraspinatus	Suprascapular	C5 (C6)	Arm abducted against resistance (not isolated). With arm pronated and elevated 90° in plane of scapula, downward pressure is applied.
Infraspinatus	Suprascapular	C5 (C6)	Arm at side with elbow flexed 90°. Examiner resists external rotation.
Teres minor	Axillary	C5–C6 (C7)	Same as for infraspinatus
Pectoralis major	Medial and lateral pectoral	C5–T1	With arm flexed 30° in front of body, patient, adducts against resistance.
Pectoralis minor	Medial pectoral	C8, T1	None
Coracobrachialis	Musculocutaneous	(C4) C5–C6 (C7)	None
Biceps brachii	Musculocutaneous	(C4) C5–C6 (C7)	Flexion of the supinated forearm against resistance.
Triceps	Radial	(C5) C6–C8	Resistance to extension of elbow from varying position of flexion.

[a]Numbers in parentheses indicate a variable but not rare contribution.
From Rockwood CA, Matsen FA III (eds): The Shoulder, Vol I. Philadelphia, WB Saunders, 1990, with permission.

Abnormal Shoulder Differential Diagnosis

Table 39-4. Abnormal Shoulder Exam: Differential Diagnosis — Make the Primary Diagnosis

INVOLVED JOINT	DIAGNOSIS	PATHOMECHANICS	MOST COMMON SPORTS
Glenohumeral	Instability Direction Unidirectional Multidirectional	 Contact Noncontact	Collision—Football, Gymnastics, cheerleading, swimming
	Labral tear Articular side	Distraction/compression Distraction	Throwing, weight lifting Throwing, baseball
	Rotator cuff tear		
Subacromial	Bursal-sided rotator Cuff involvement from bony impingement	Microtraumatic Compression	Tennis, golf
	Subacromial arch AC Joint Arthrosis/osteolysis	Compression	Weight lifting Older age
Acromioclavicular	Arthrosis	Macro and micro contact Loading	Weight lifting
	Instability, sprain	Macro contact	Rugby, ice hockey, equestrian
Scapulothoracic	Neurologic Long thoracic nerve involvement	Serratus anterior weakness	Baseball, archery
	Physiologic dysfunction	Underlying lack of strength	Swimming, tennis

Rotator Cuff

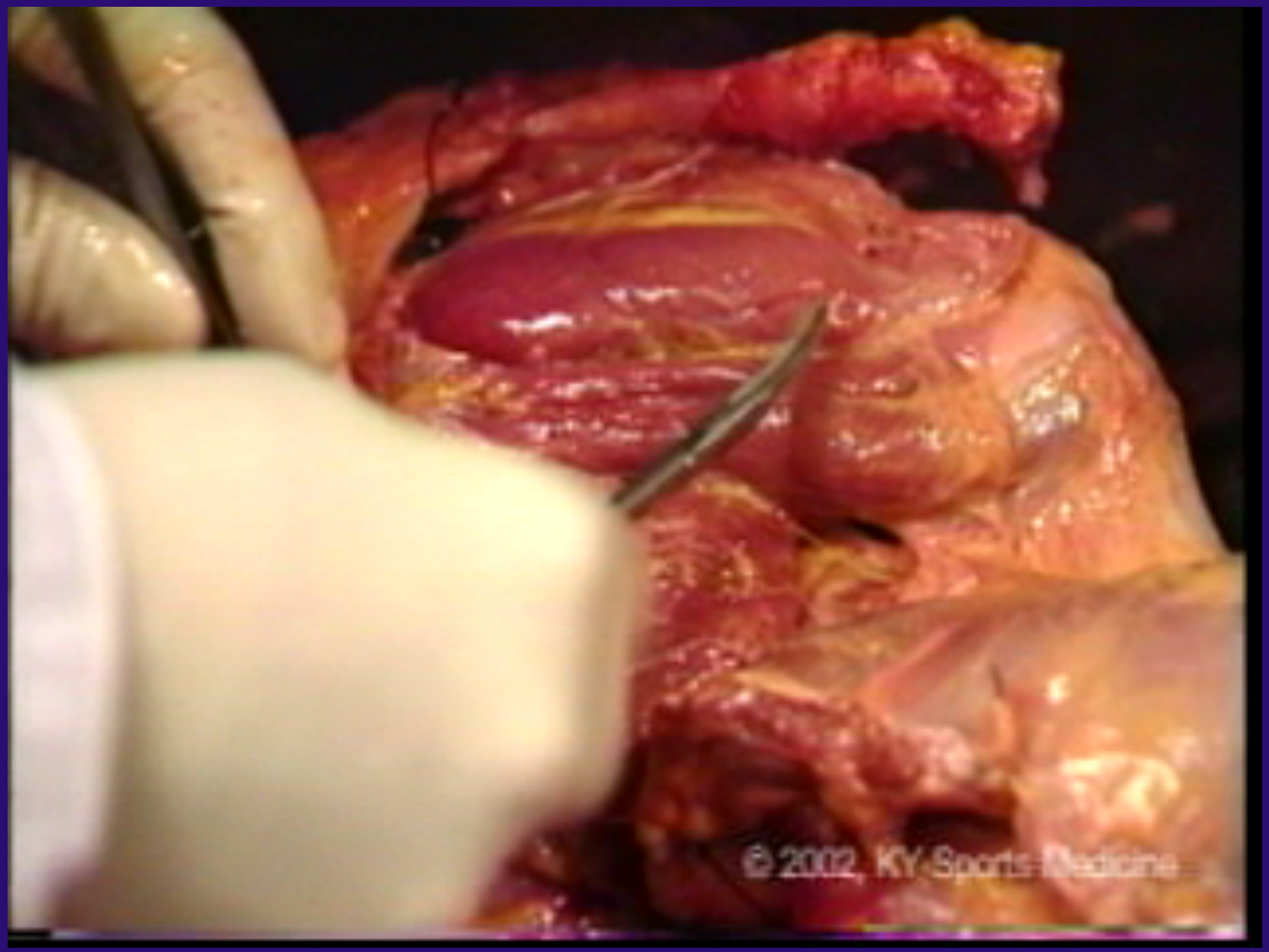

ROTATOR CUFF

Supraspinatus
Infraspinatus
Teres minor

The "SIT" Muscles

Palpate and Manual Muscle Test
Arm in varying degrees of abduction and rotation

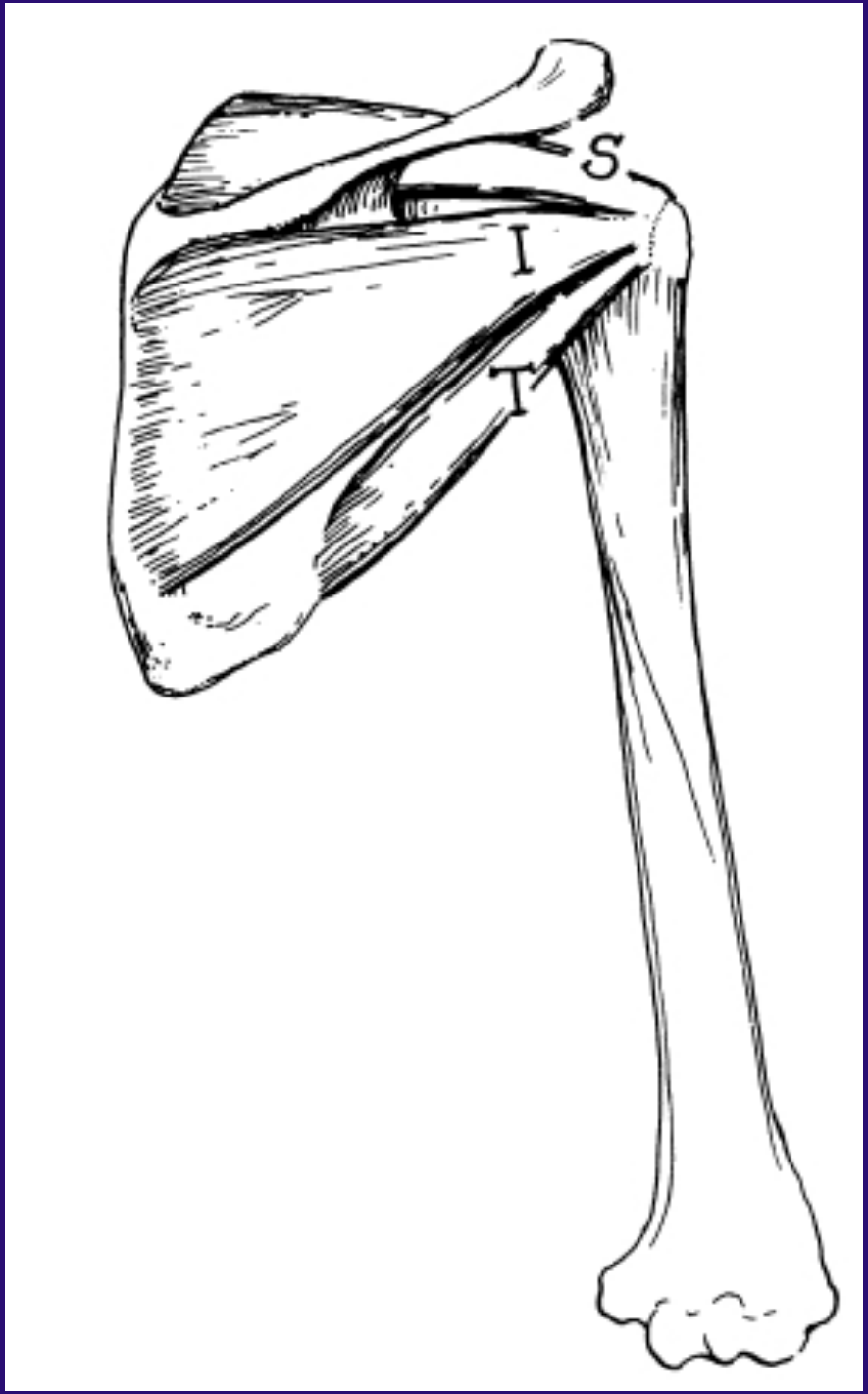

Internal and External Rotators

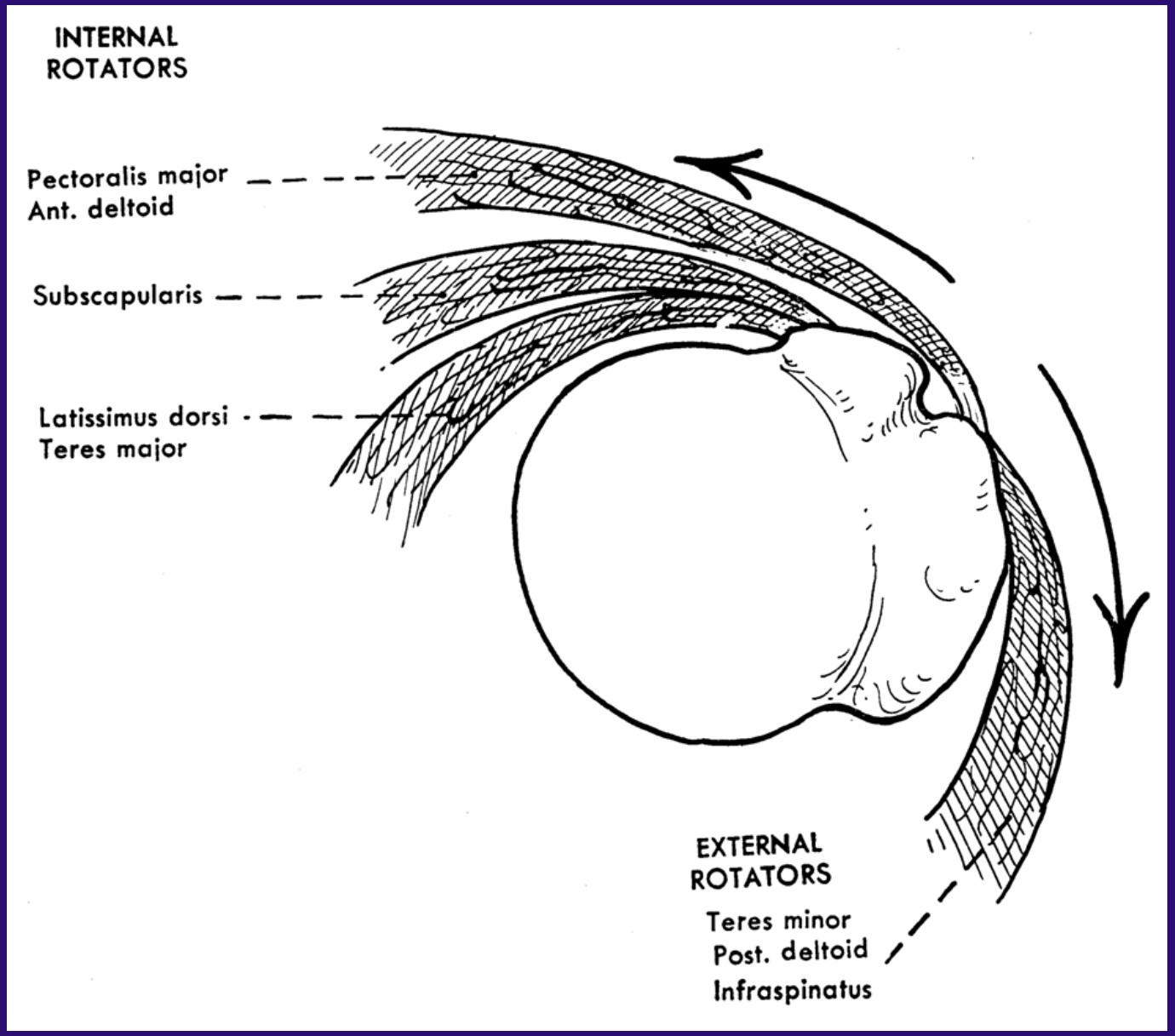

Rotator Cuff Testing

- Empty can position
- Weakness in external rotation

Be Specific:

The diagnosis should define the structure that is injured and the condition

Diagnosis Rotator Cuff

- Inflammation
- Tear
  - Partial vs. Complete
  - Articular side vs. Bursal side

Complete Tear

- Suspension bridge
  - Free side of tear (cable)
  - Attachments of tear
    or (supports at each end)

Mobilization of cuff and view of sutures pulling cuff back to greater tuberosity

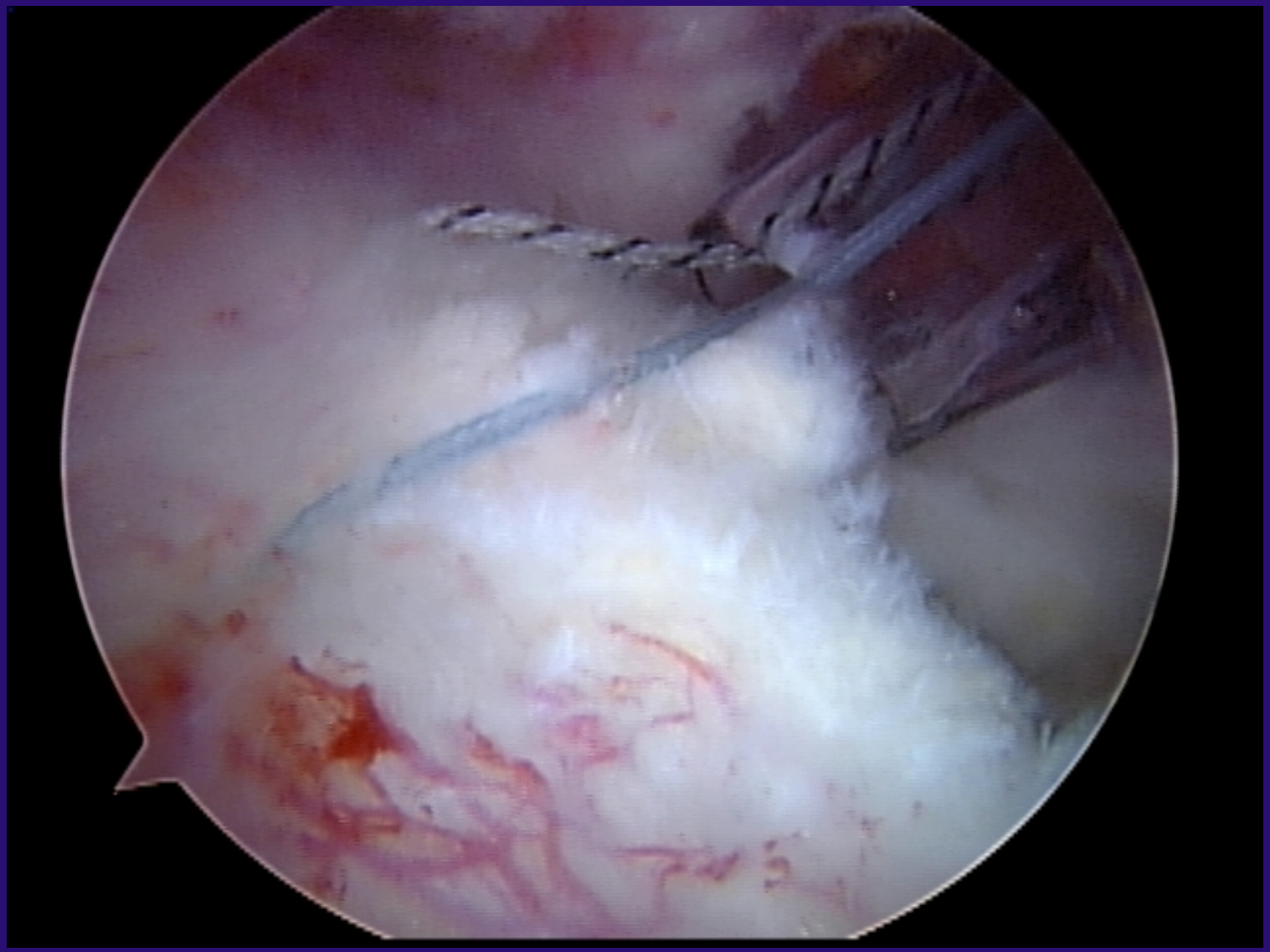

75 YO Male: Massive Rotator Cuff Tear

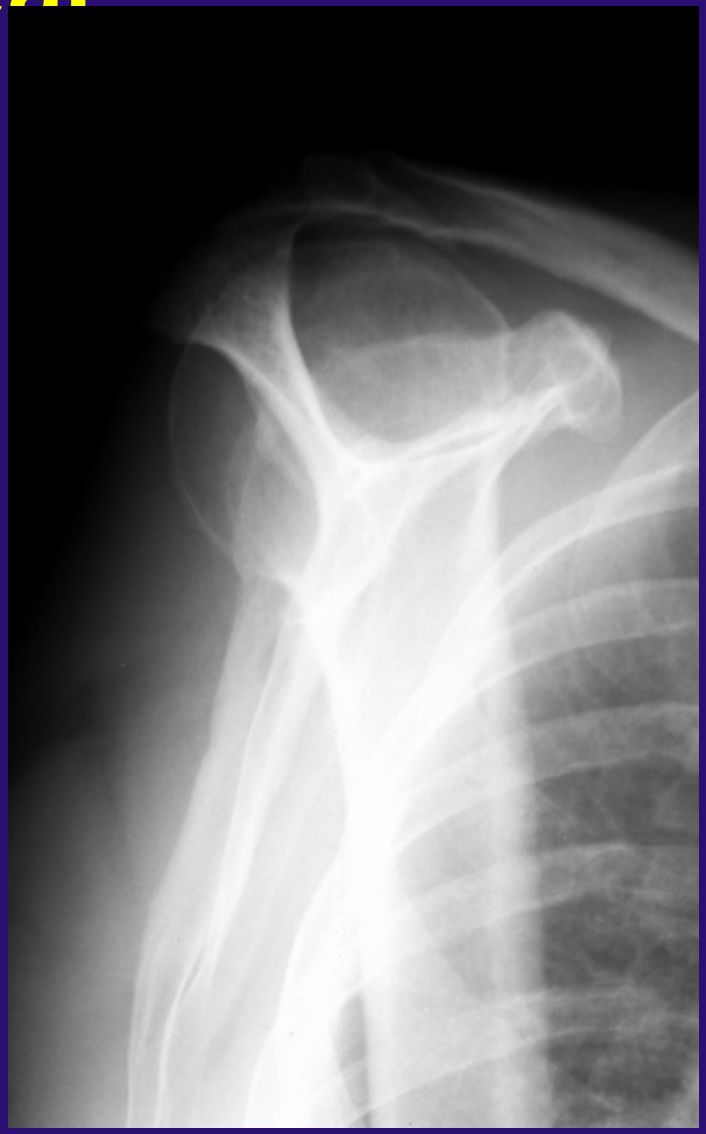

75 YO Male: Massive Rotator Cuff Tear

MRI

- Full Thickness supraspinatus tear

Window shade to sill
(cuff) (greater tuberosity)
Use this comparison for patient education

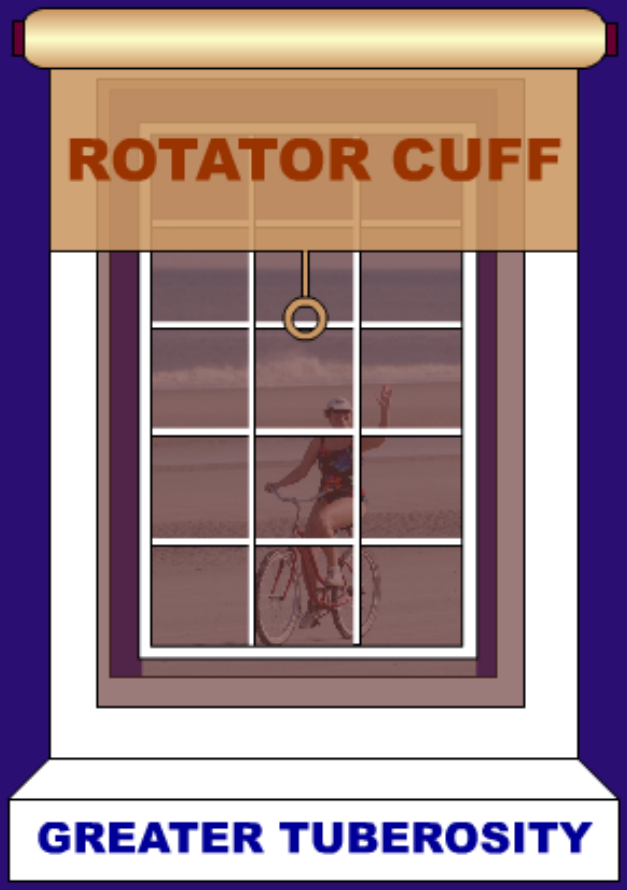

MASSIVE

SIZE of TEAR

There are many clinical tests named after someone. Instead of description by name:

- Think of the motion of joint and forces you apply:
  - Is it labral?
    - (Axial loading like McMurray's)
  - Is it the rotator cuff?
    - (compressing or impinging)
  - Is it instability?
    - (distraction of joint capsule subluxing the humeral head)

Named Tests vs. Movement Description

- Many tests for biceps tendon disorders
- Think about patient history, anatomy and move the arm, load the joint to reproduce patient's symptoms

Do the most painful part of the exam LAST

Tests for proximal biceps tendon dysfunction – long head

- Ludington's
- Yergason's
- Abbott and Saunders'
- DeAnquin's
- Matsen's
- Speed's

Include these for complete exam
Rarely isolated biceps problem
Think associated tear subscap/labrum/RC

Abbott and Saunders' test

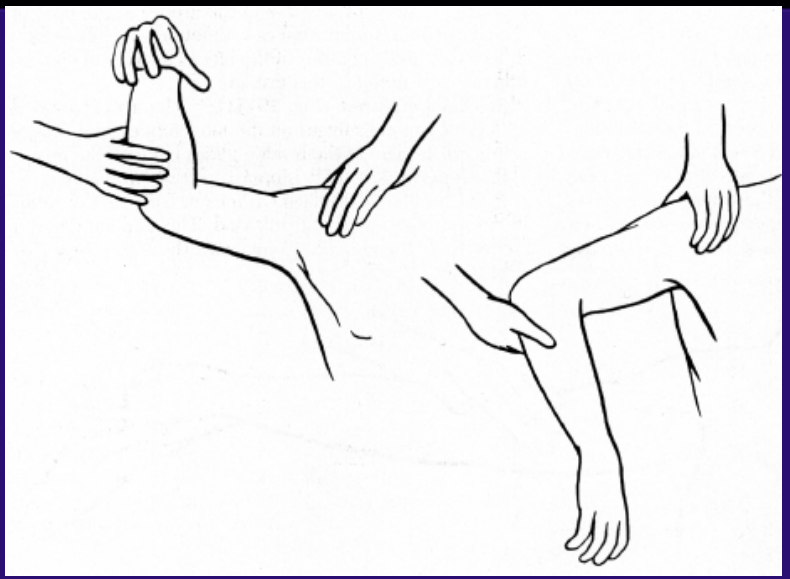

DeAnquin's test

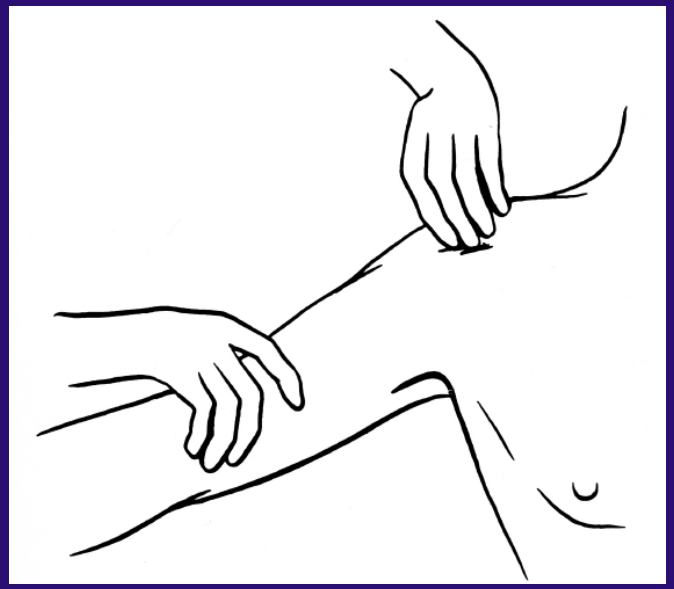

Matsen's test

from - Burkhead WZ, Arcand MA, Zeman C, Habermeyer P, Walch G, *The Biceps Tendon,* In: The Shoulder, Rockwood CA, Matsen FA (Saunders, Philadelphia, 1998), 1036.

Speed's test

The biceps resistance test is performed with the patient flexing the shoulder against resistance, with the elbow extended and the forearm supinated.

Pain referred to the biceps tendon area constitutes a positive result.

from - Burkhead WZ, Arcand MA, Zeman C, Habermeyer P, Walch G, *The Biceps Tendon,* In: The Shoulder, Rockwood CA, Matsen FA (Saunders, Philadelphia, 1998), 1035.

Yergason's test

With the arm flexed, the patient is asked to forcefully supinate against resistance from the examiner's hand.

Pain referred to the anterior aspect of the shoulder in the region of the bicipital groove constitutes a positive result.

from - Burkhead WZ, Arcand MA, Zeman C, Habermeyer P, Walch G, *The Biceps Tendon,* In: The Shoulder, Rockwood CA, Matsen FA (Saunders, Philadelphia, 1998), 1036.

Ludington's test

The patient is asked to put his or her hands behind the head and flex the biceps. The examiner's finger can be in the bicipital groove at the time of the test.

Subtle differences in the contour of the biceps are best noted with this maneuver. In this illustration the patient has a ruptured biceps at the left shoulder.

from - Burkhead WZ, Arcand MA, Zeman C, Habermeyer P, Walch G, *The Biceps Tendon,* In: The Shoulder, Rockwood CA, Matsen FA (Saunders, Philadelphia, 1998), 1037.

Labrum & Capsule

- Labral Function
- Stability
- Bumper
- Biceps attachment
- Shock absorber

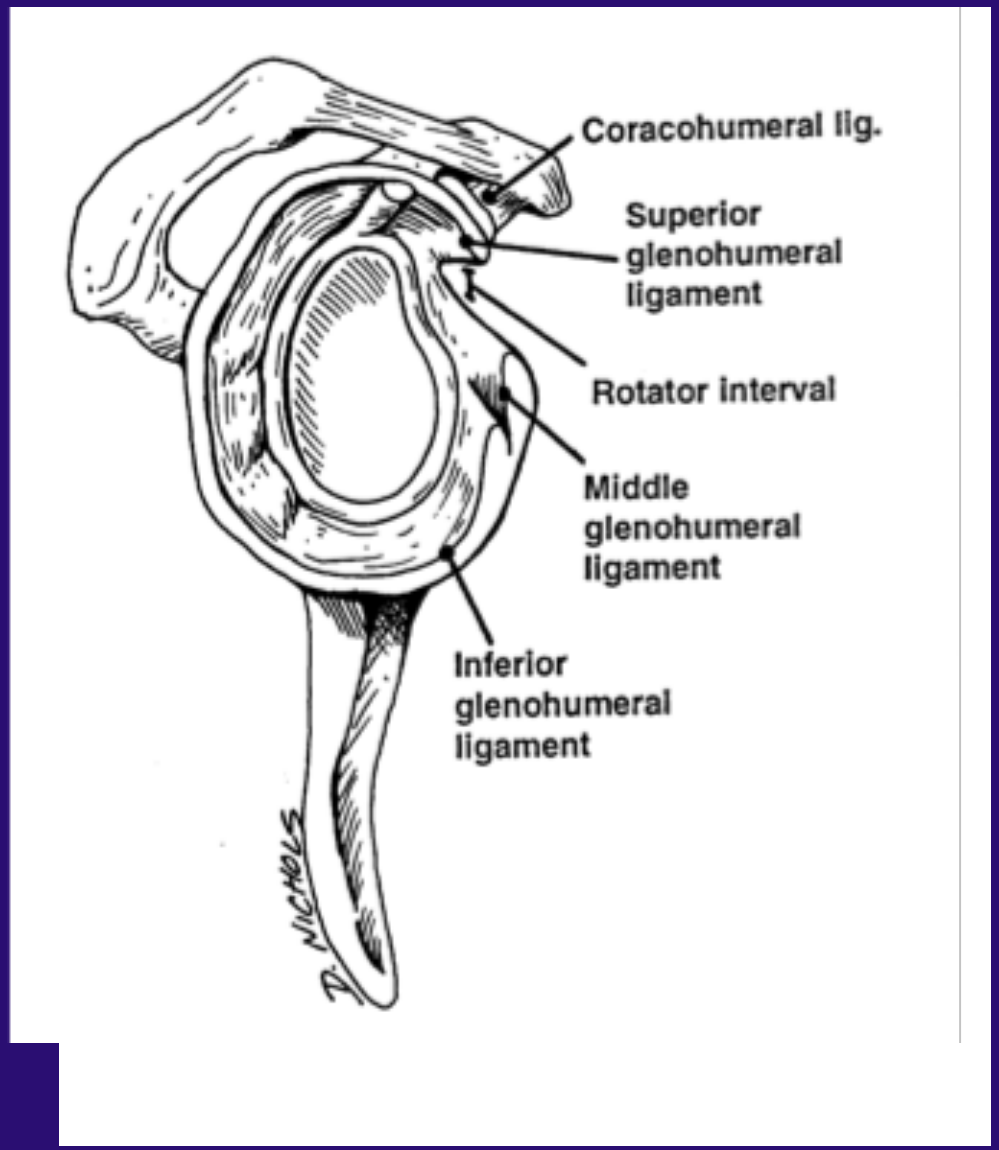

Glenoid : Labrum

Tee : Golf Ball
Seal : Ball
Contact Lens : Eyeball



- Prospective study
- 61 shoulders, 62 patients
- Tests Used
  - Jobe relocation test
  - O'Brien test
  - Anterior apprehension test
  - Bicipital groove tenderness
  - Crank test
  - Speed test
  - Yergason test
- Only O'Brien and Jobe relocation test were statistically correlated with presence of labrum tear, including SLAP
  - Other five not found useful for labral tears
  - None of the tests or combinations statistically valid for SLAP lesion only

Guanche CA and Jones DC, "Clinical Testing for Tears of the Glenoid Labrum," in Arthroscopy: The Journal of Arthroscopic and Related Surgery, vol. 19, no. 5 (May-June 2003), 517-523.


SPORT
MEDICI


ENTUCK
SPORT
MEDICI

O’Brien’s Test

Shoulder: Peel-back sign

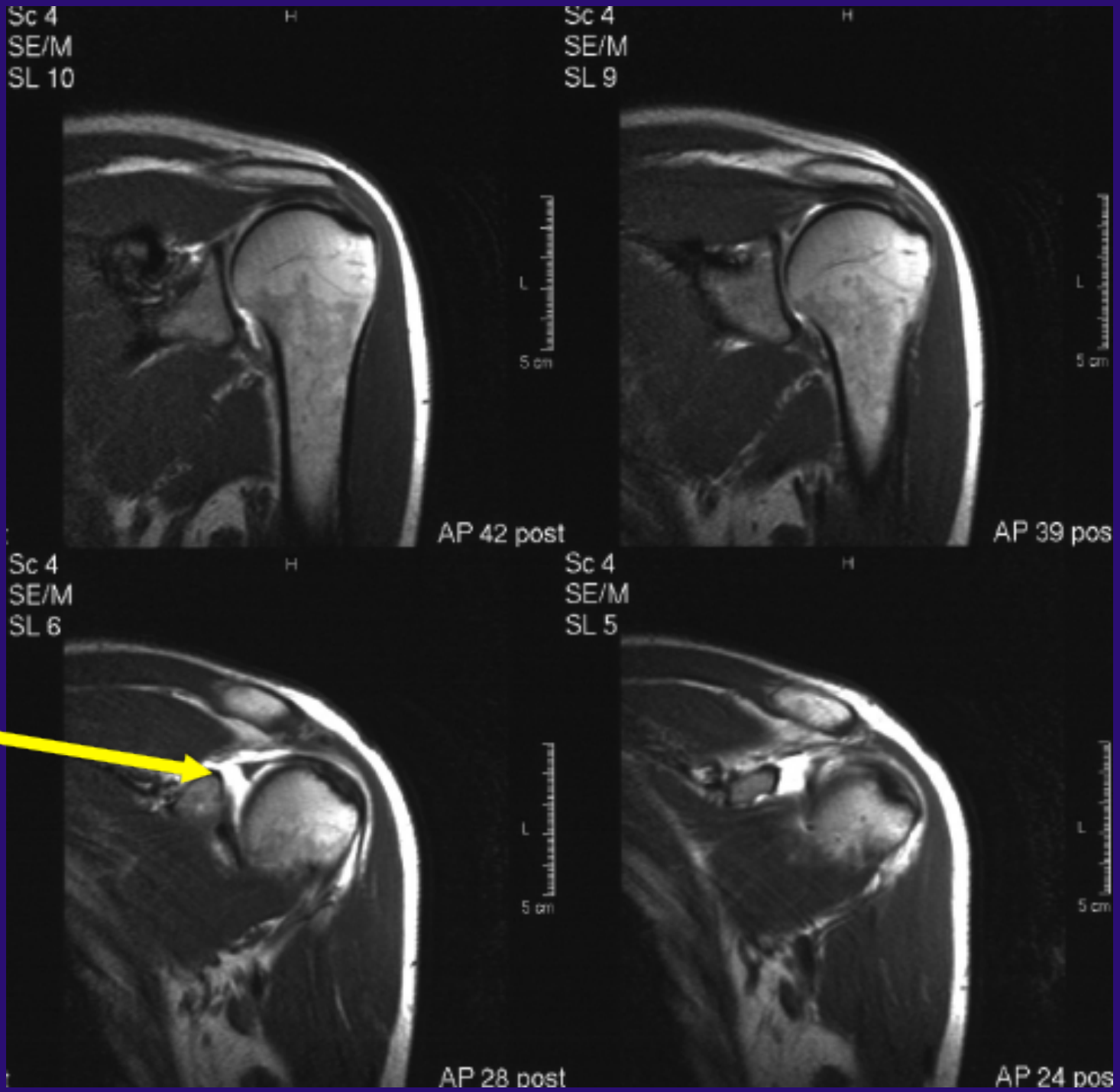
Sc 4
SE/M
SL 10
H
L
5 cm
AP 42 post
Sc 4
SE/M
SL 9
H
L
5 cm
AP 39 pos
Sc 4
SE/M
SL 6
H
L
5 cm
AP 28 post
Sc 4
SE/M
SL 5
H
L
5 cm
AP 24 pos

If SLAP tear in young pitcher, assess RC for tear

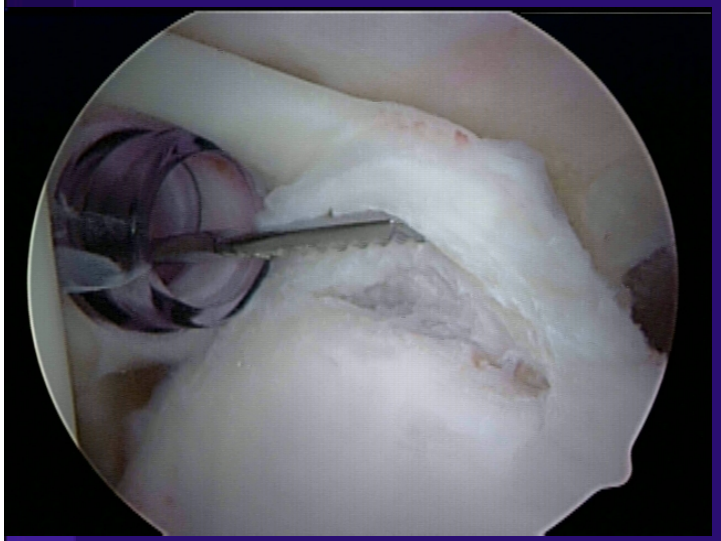
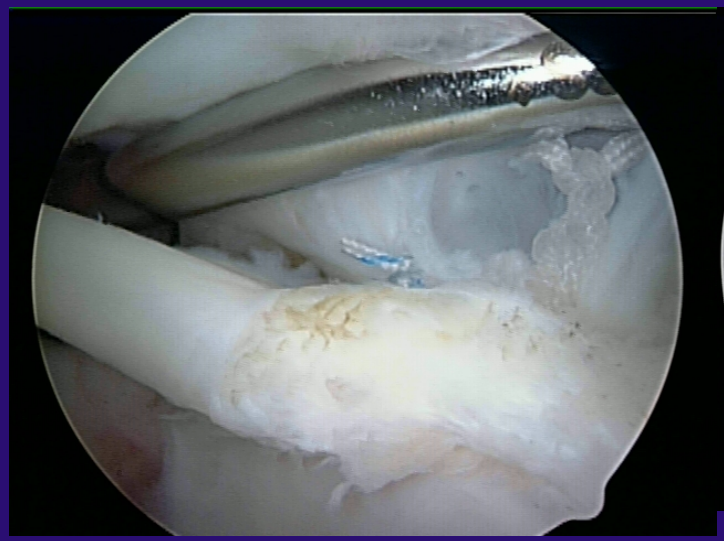
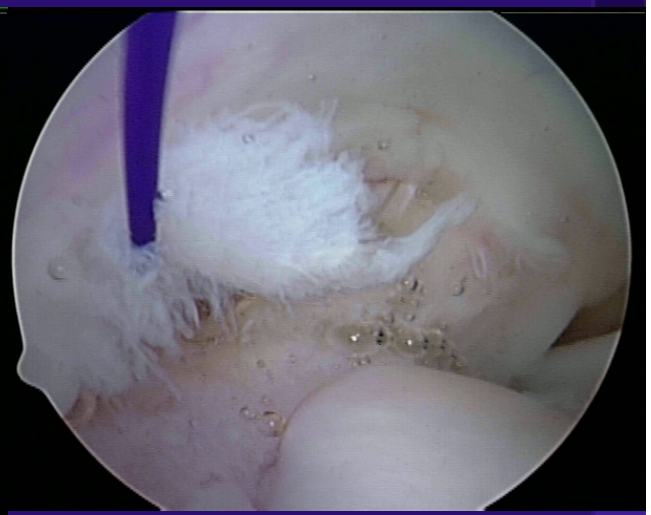
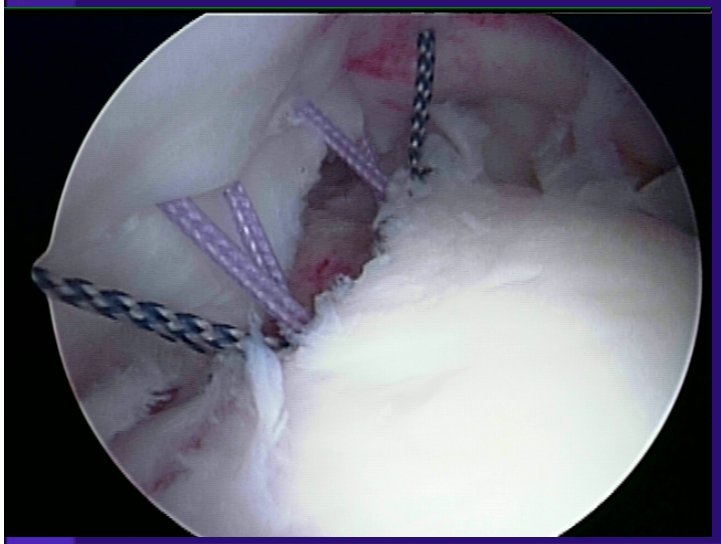
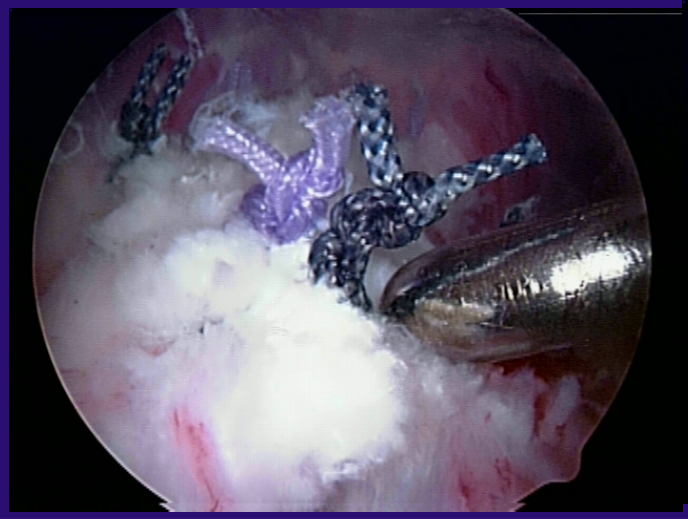
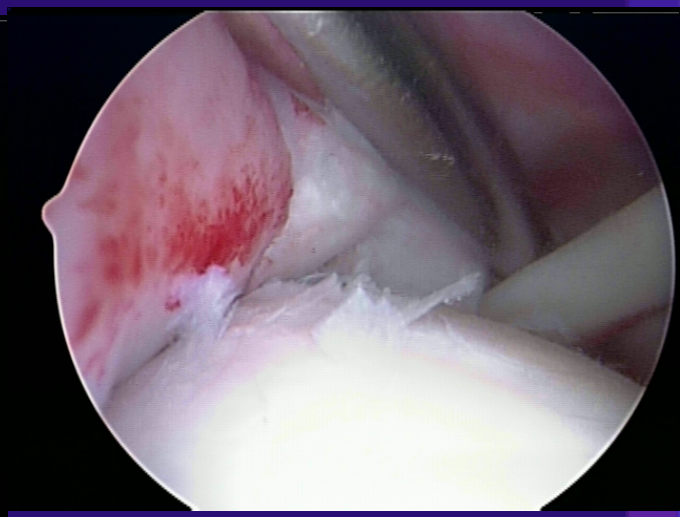

Shoulder Palpation Crank Tests

Shoulder Stability

18 YO Freshman Football Athlete

- 18 YO Freshman RB for EKU w/ dominant right shoulder injury
- Opening game, 8/31/2000
- No previous H/O injury
- Dead Arm Complaints
- Mechanism of Injury thought to be a lateral blow to the shoulder while being tackled

Clinic Radiographs

- Confirm humeral head radiolucency consistent with Hill-Sachs lesion

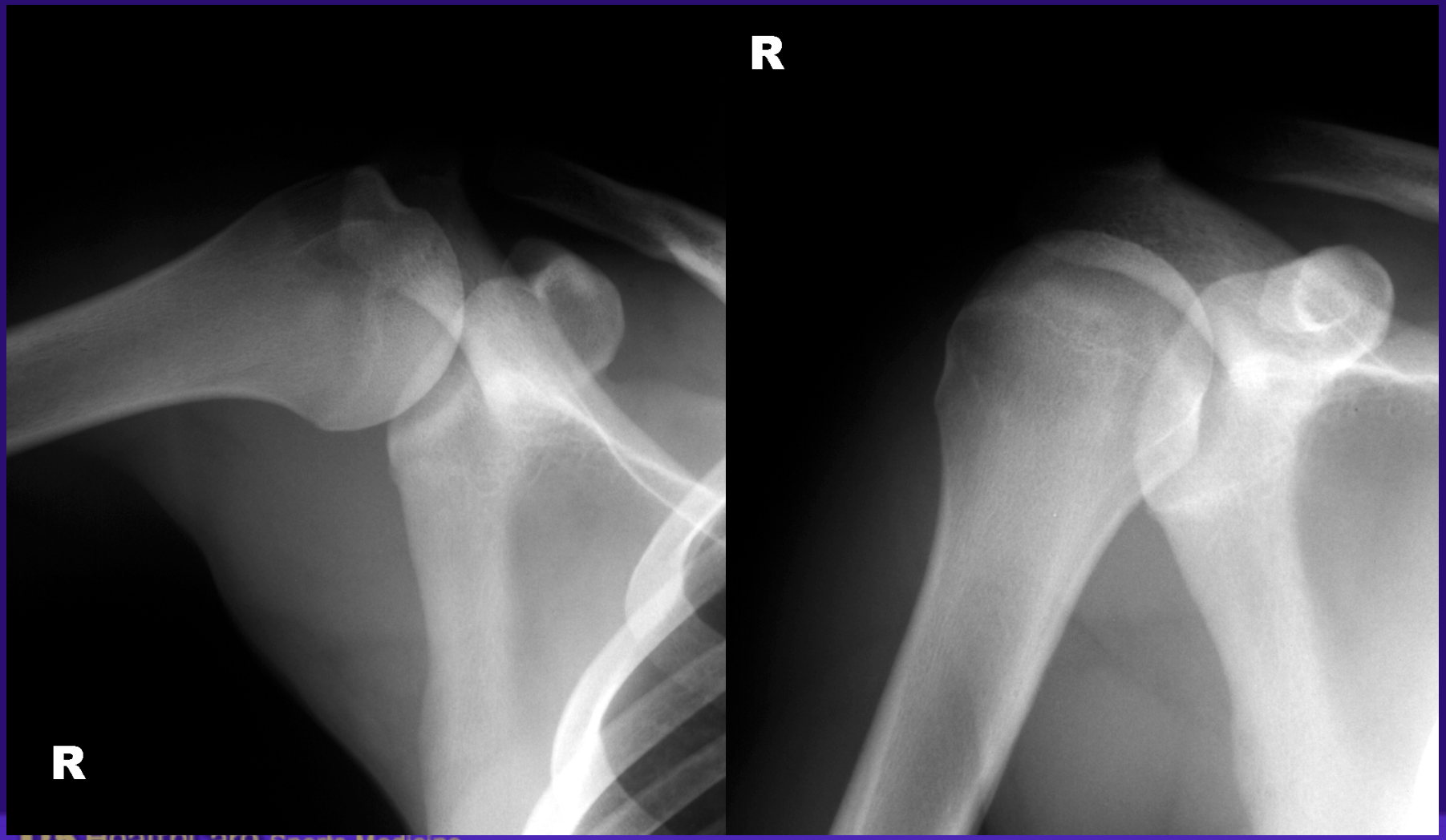

Axillary views

Regular

Modified

MRI

- Hill-Sachs lesion approx. 20%
- Anteroinferior Labral Detachment
- Anterosuperior Labral Detachment

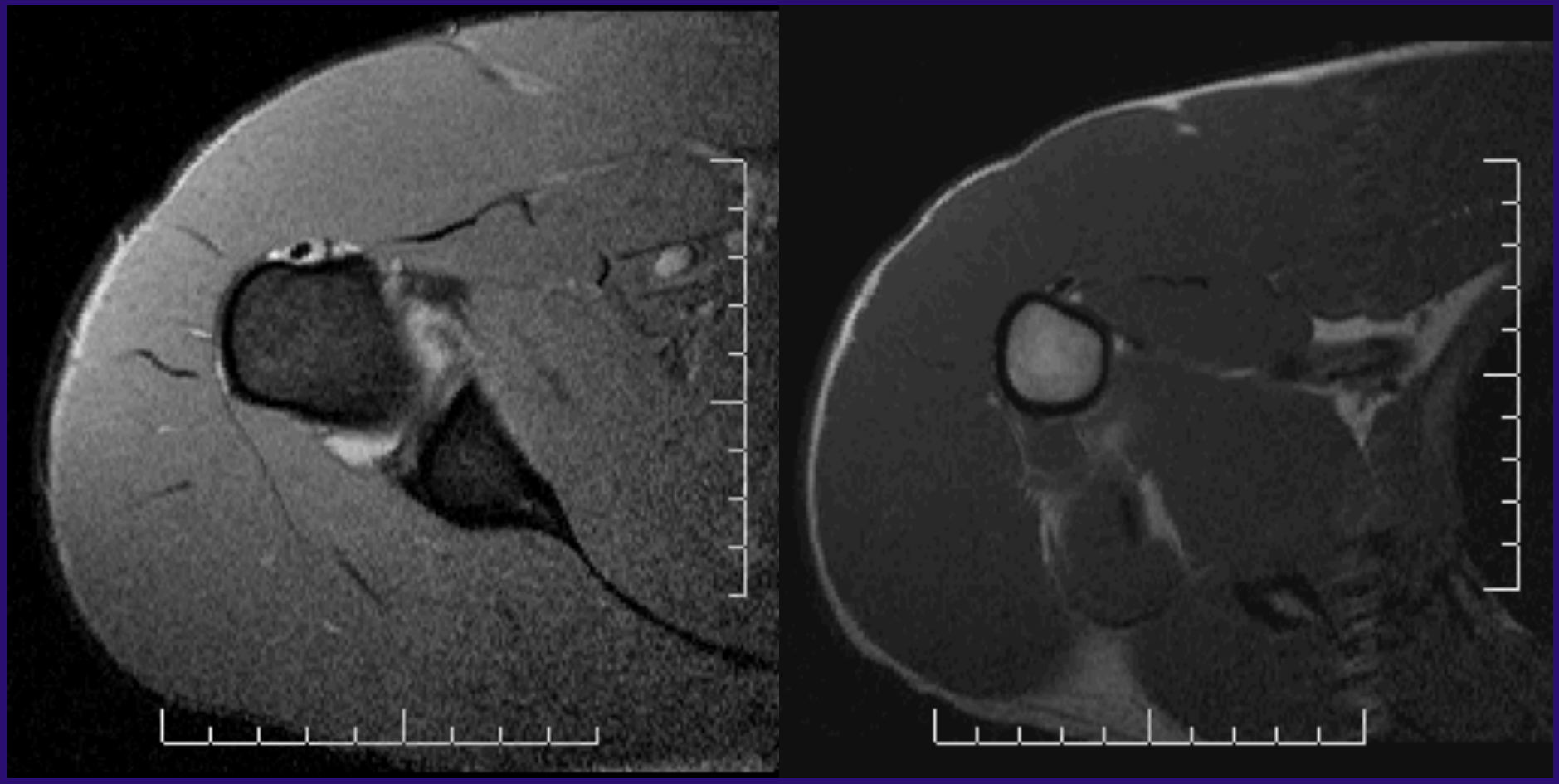

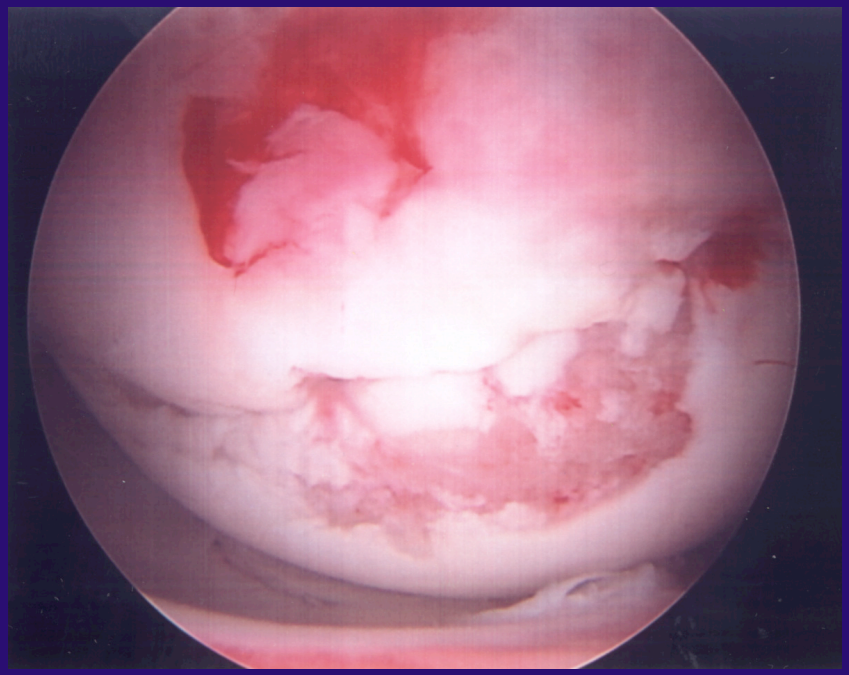

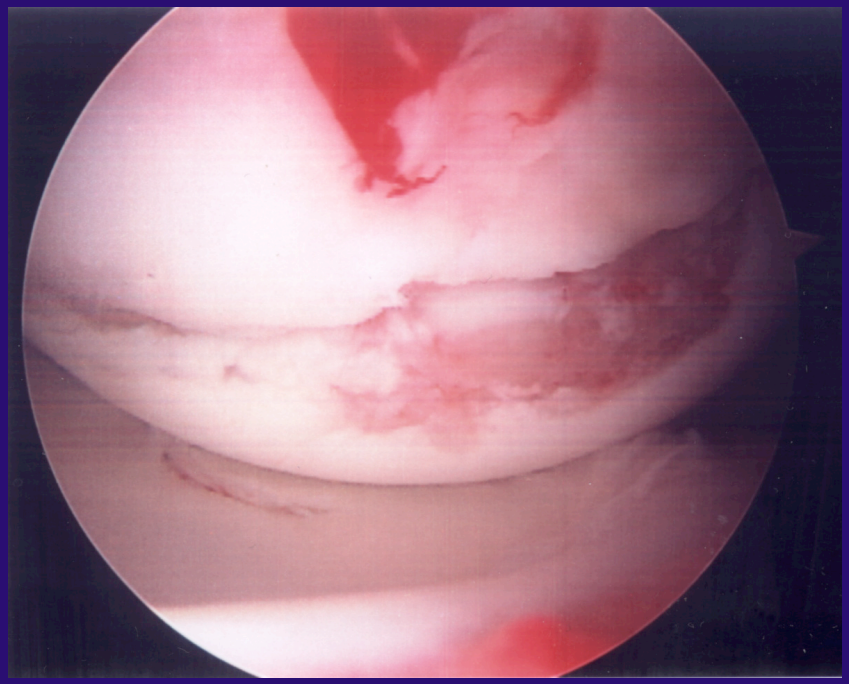

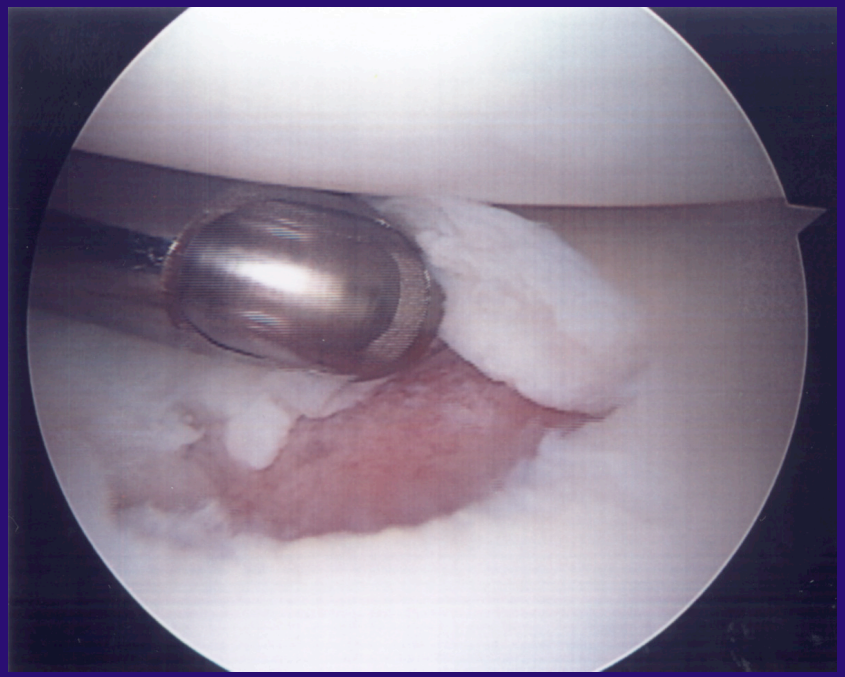

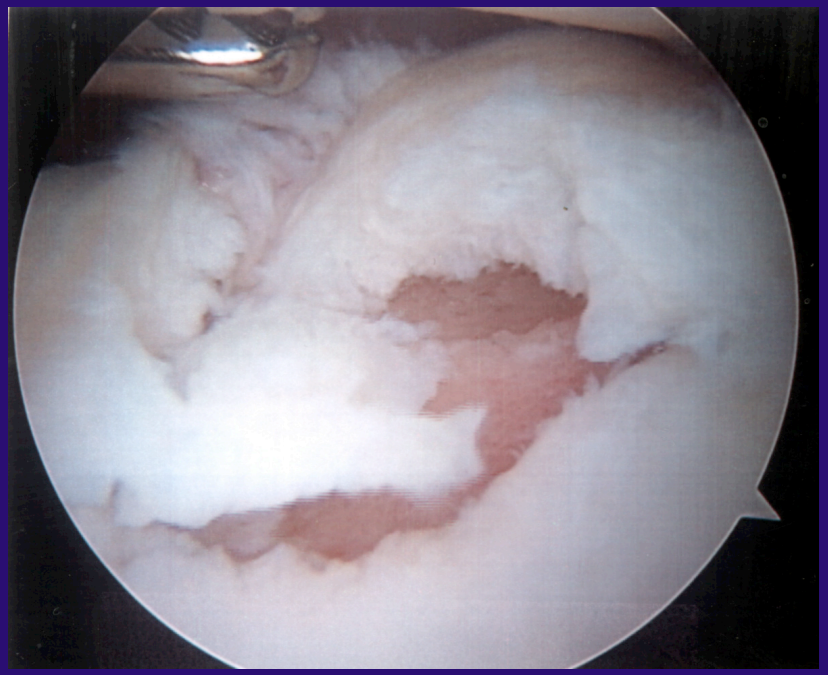

Posterior Instability Test

Prone Posterior Instability Test

Vicious Cycle: Laxity to Instability

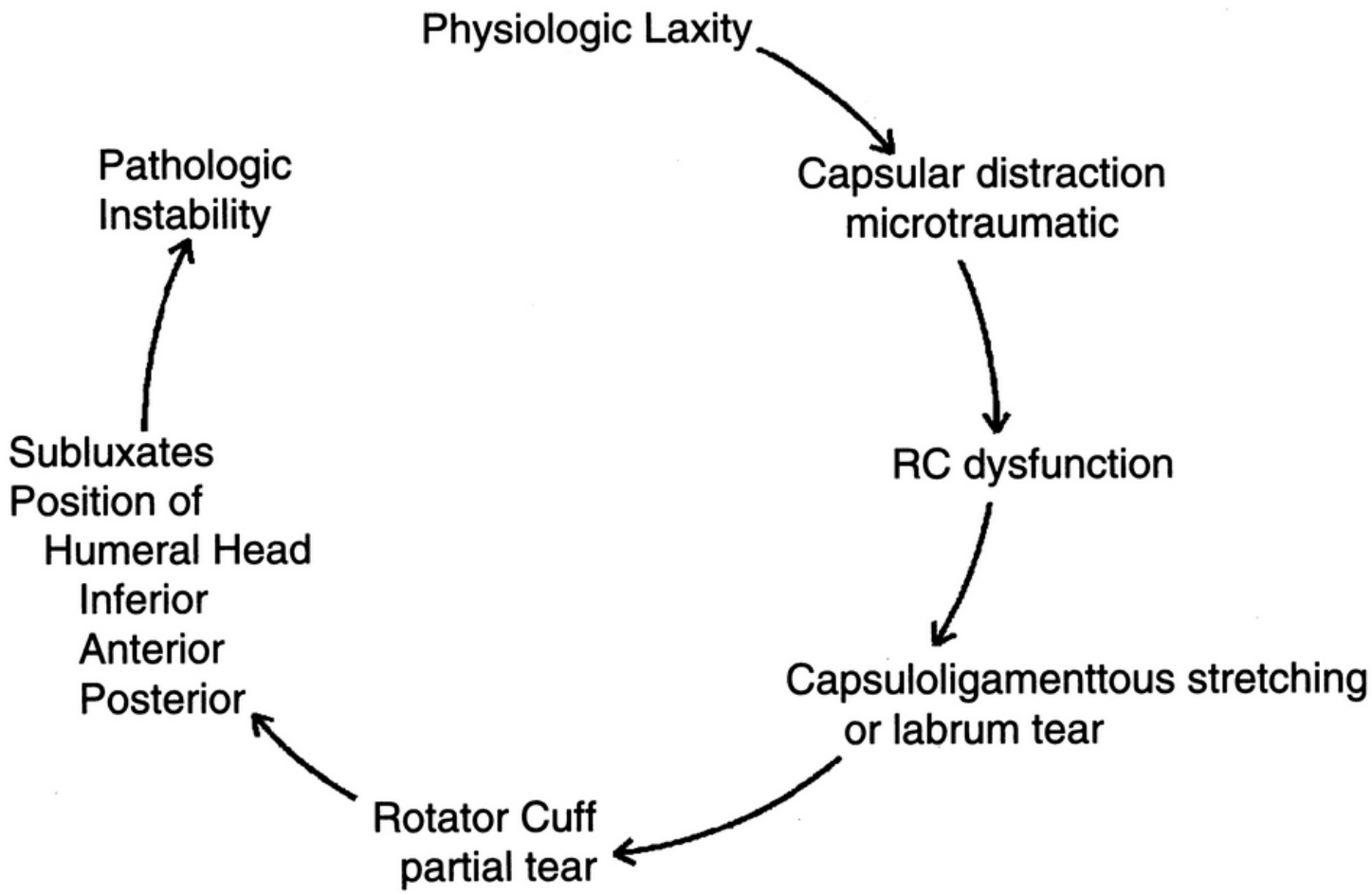

Figure 39-29. The vicious cycle in which physiologic laxity can lead to pathologic instability is shown schematically.

Multi-Directional Instability

- Voluntary posterior direction - symptomatic

S/P Open anterior shoulder reconstruction
Multi-Directional Instability, bilateral shoulders.

More symptomatic on operated right side.

18 YO Right-Hand-Dominant Discus Thrower

- Threw the discus
- Felt pop, pain,inability to move her arm
- Went to the emergency room

Posterior Dislocation

- X-rays showed humeral head posteriorly dislocated on axillary view
- This direction of dislocation still is missed in emergency rooms

Posterior Dislocation

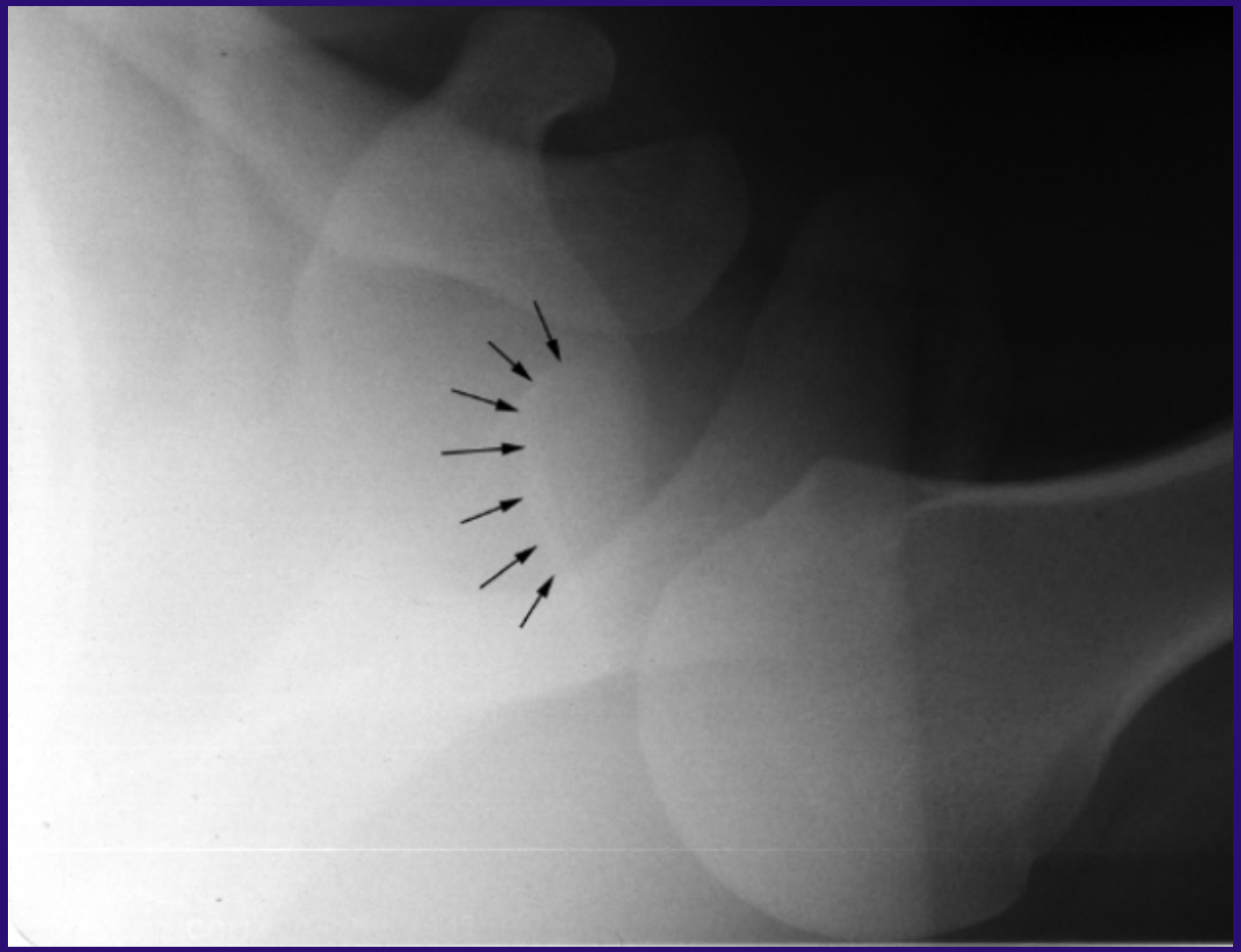

EUA Severe Posterior Instability

ER view
Axillary

Posteriorly
Dislocated

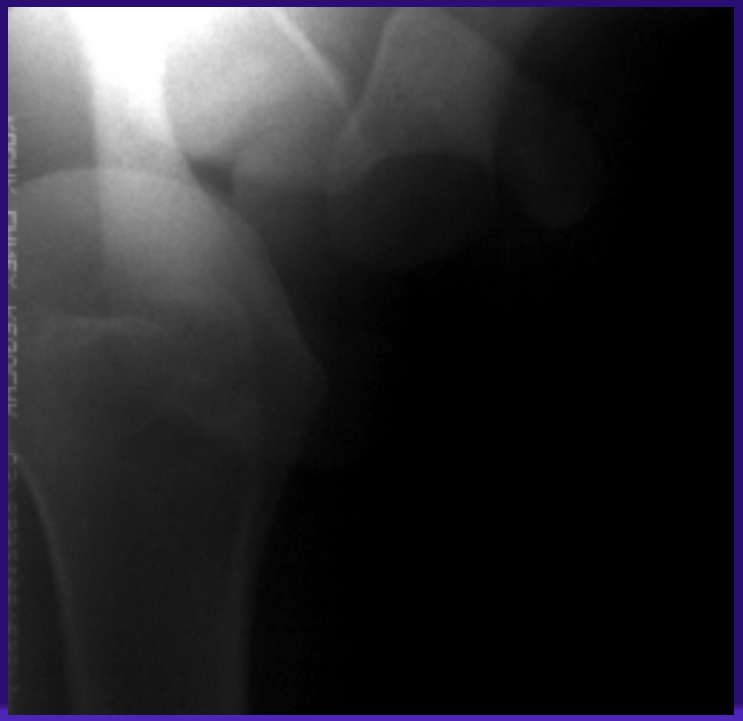

Posteriorly dislocated

Stryker view

Shoulder Pain Algorithm: AAOS Clinical Guideline on Shoulder Pain, in *Orthopaedic Knowledge Update: Shoulder and Elbow 2* (AAOS, 2002), p. 448-455.

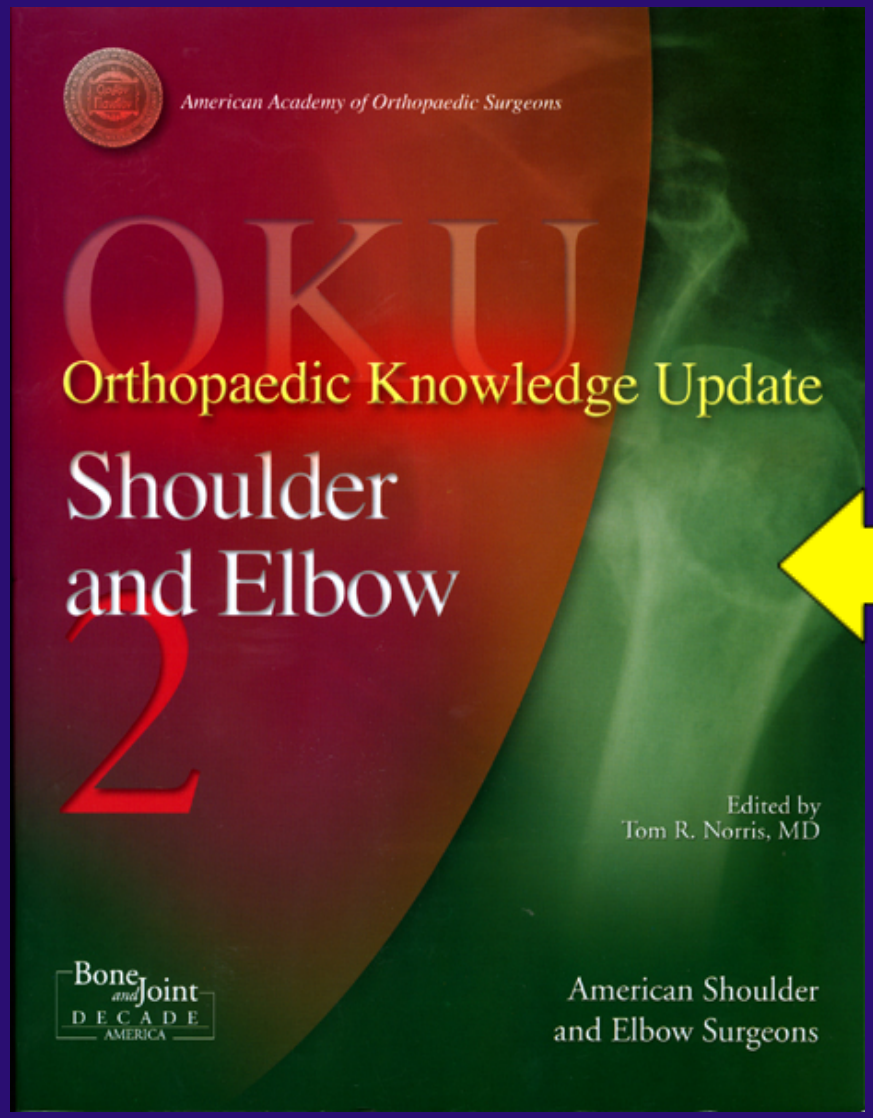

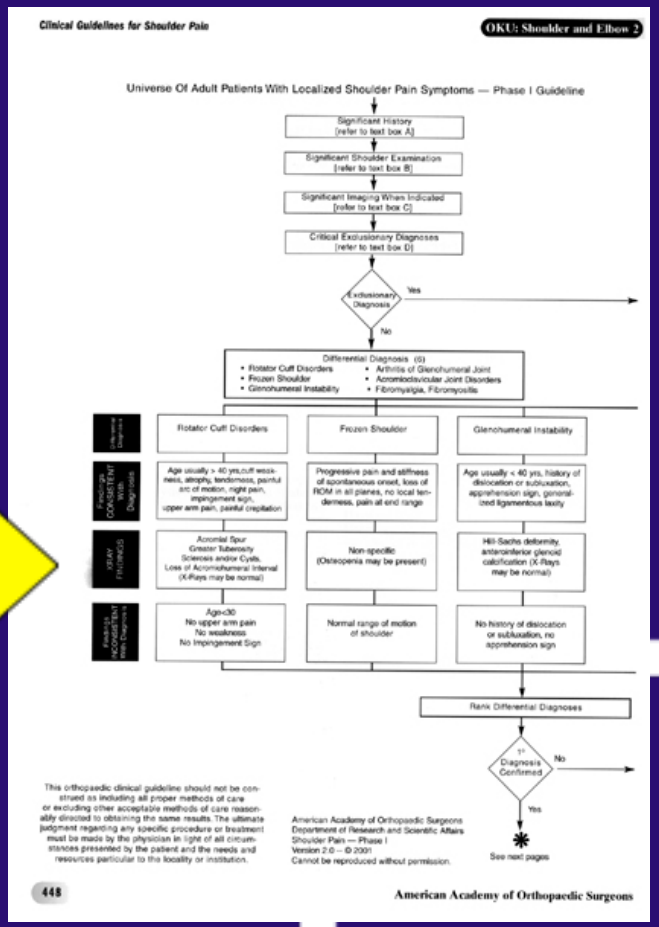

[more]

[more]

Imaging

- Plain films
- Make the diagnosis by history and physical and plain films
- Institute treatment
- Re-examine
- Then special Imaging Studies

Shoulder Pain Algorithm: AAOS Clinical Guideline on Shoulder Pain, in *Orthopaedic Knowledge Update: Shoulder and Elbow 2* (AAOS, 2002), p. 448-455.

- Initial Imaging
  - True AP in 0º external rotation
  - Lateral in scapular plane
  - Axially view
    - When imaging studies are indicated during the initial evaluation and treatment of a patient with shoulder pain, appropriate plain "x-rays" should be obtained. More sophisticated imaging studies (such as shoulder MRI, ultrasound, or arthrography) are not indicated.

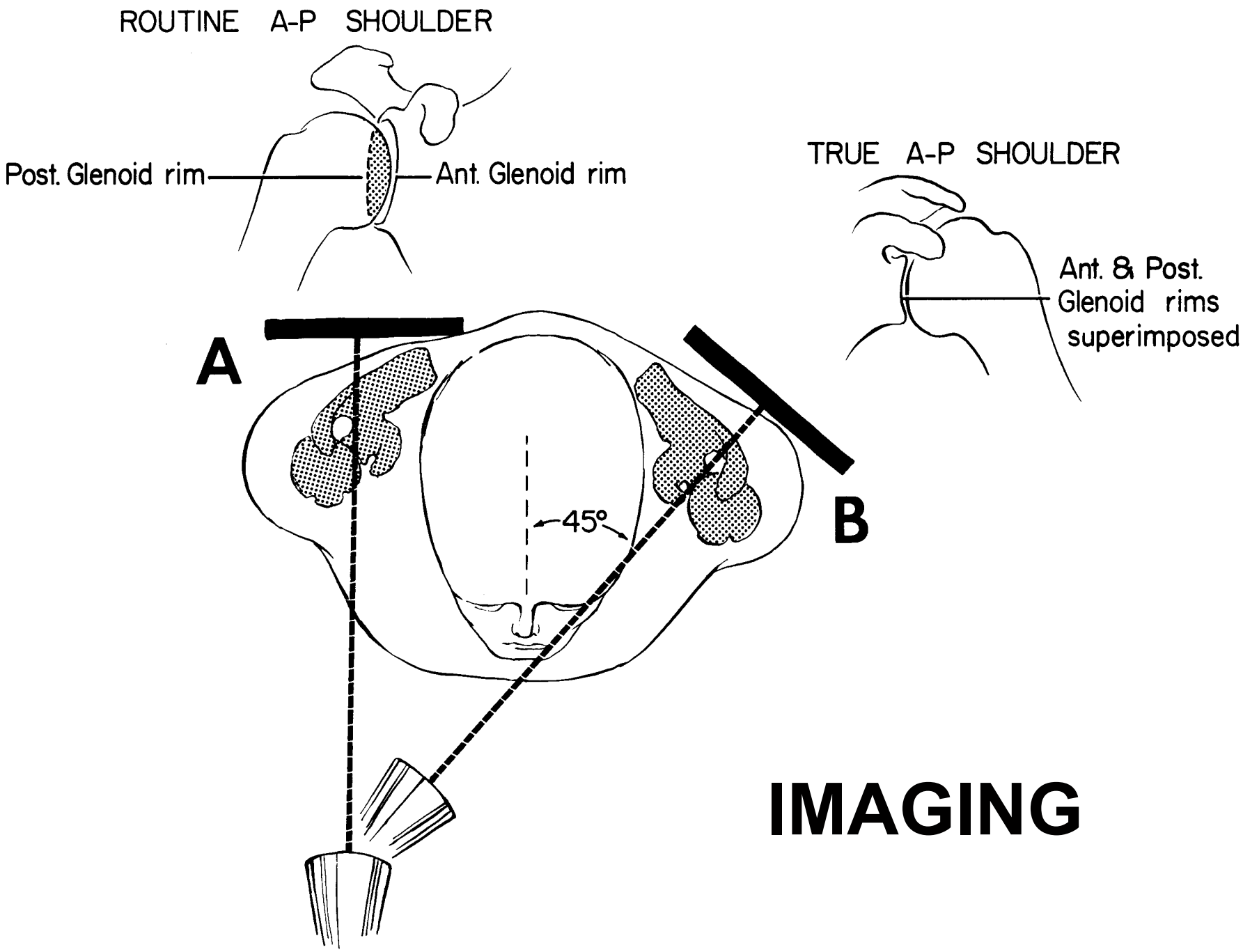
ROUTINE A-P SHOULDER
Post. Glenoid rim
Ant. Glenoid rim
TRUE A-P SHOULDER
Ant. & Post.
Glenoid rims
superimposed
A
B
45°

IMAGING

AP Internal View

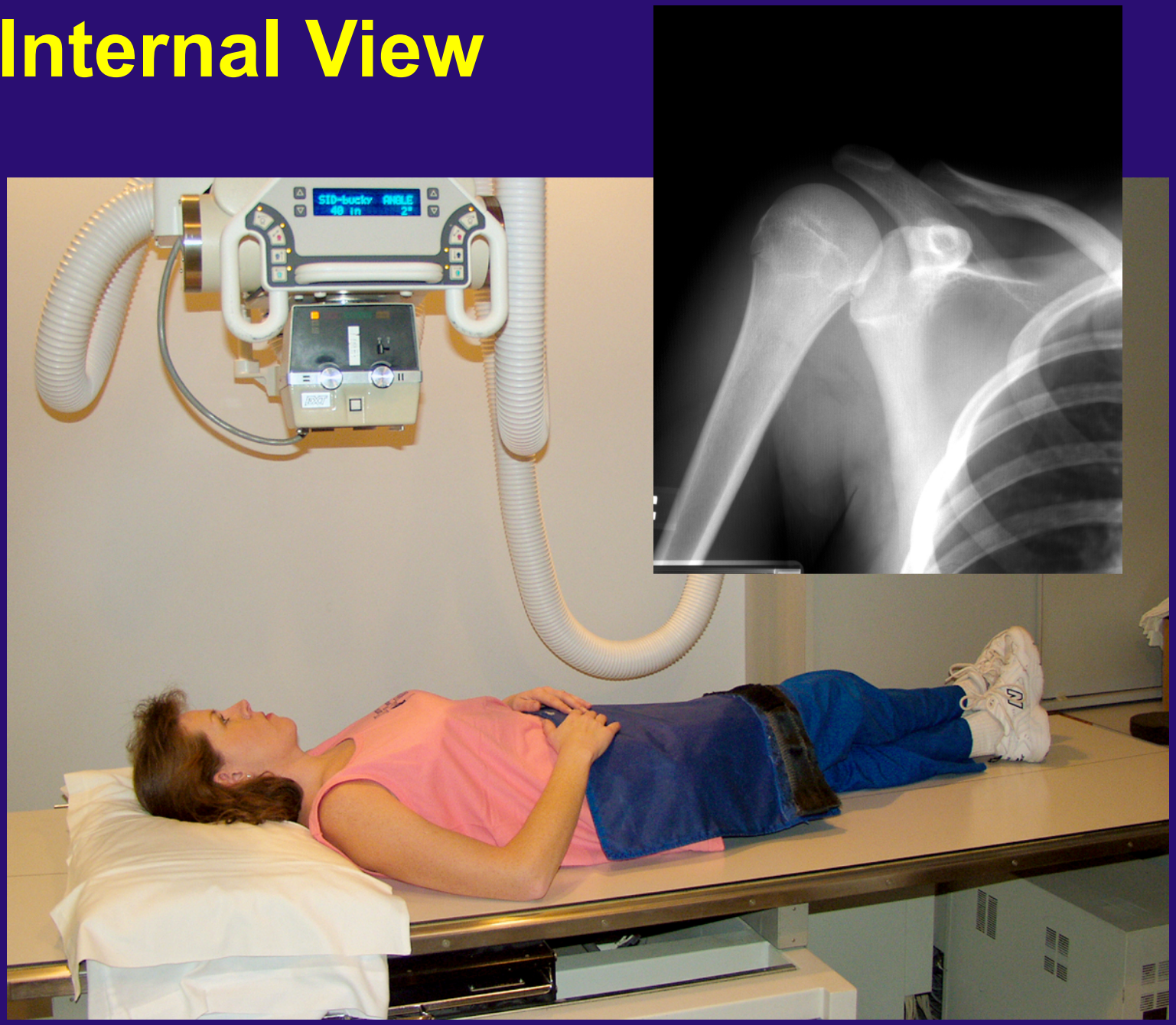

Stryker Notch View

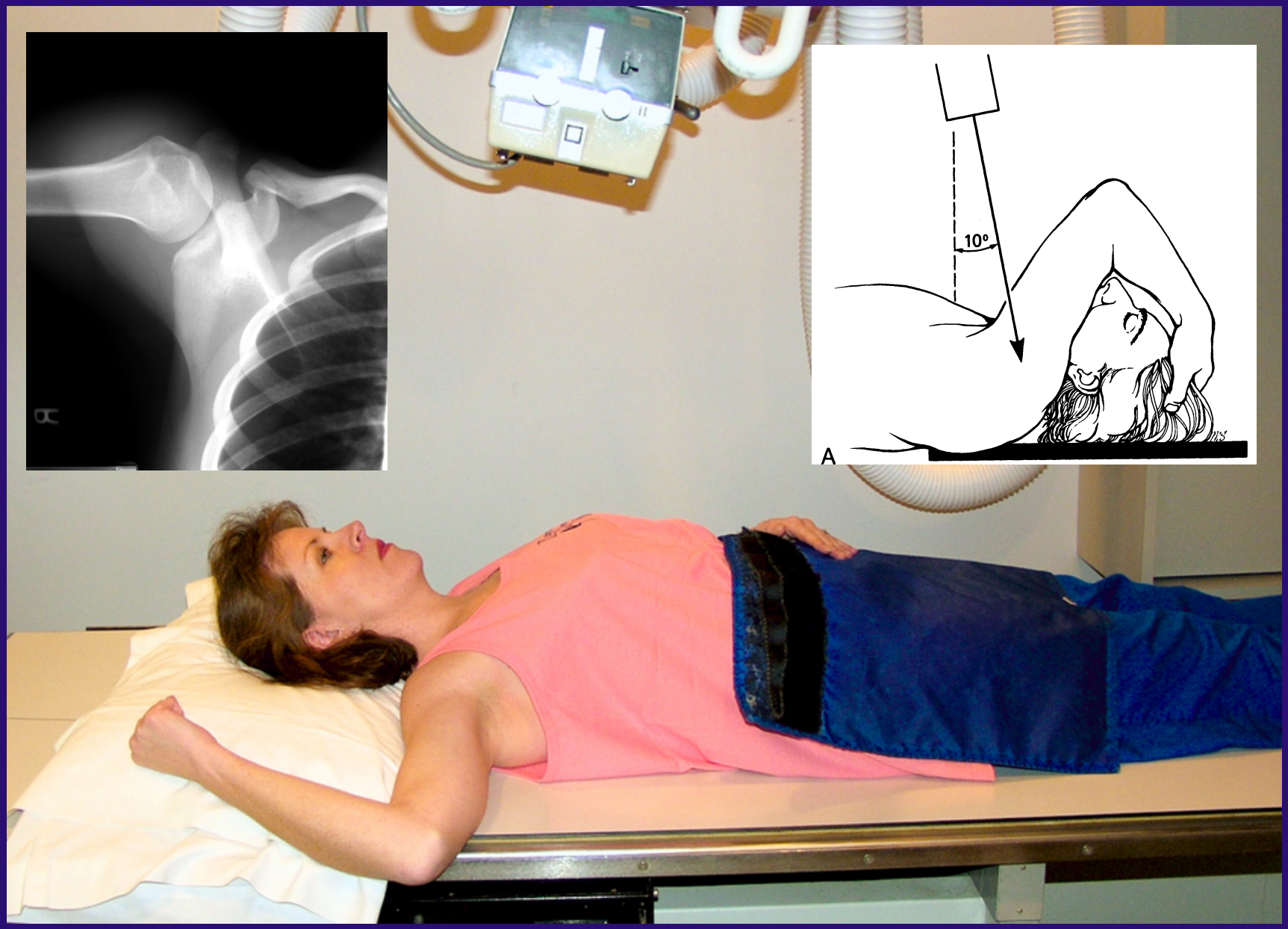

Outlet View

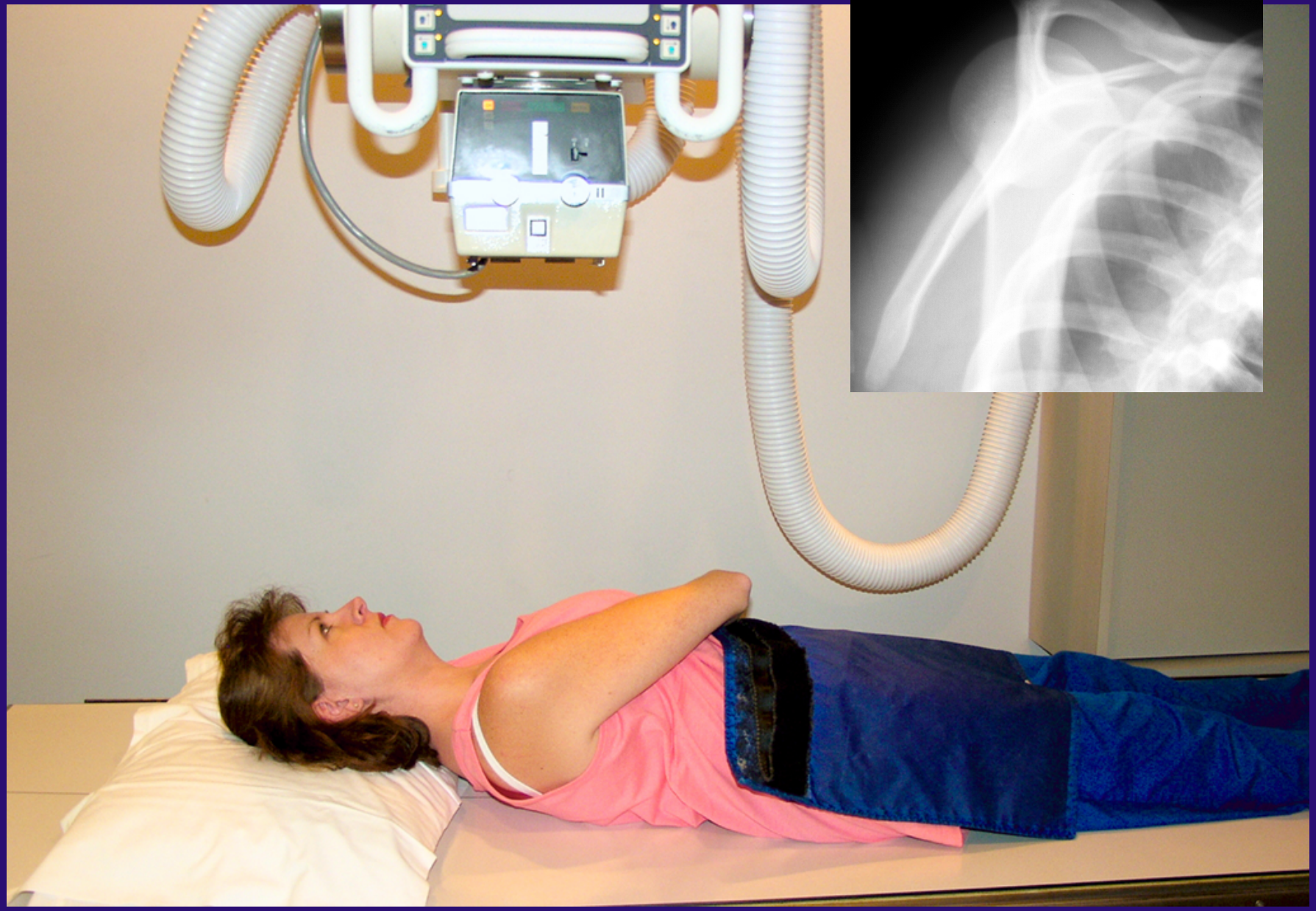

Outlet Upright View

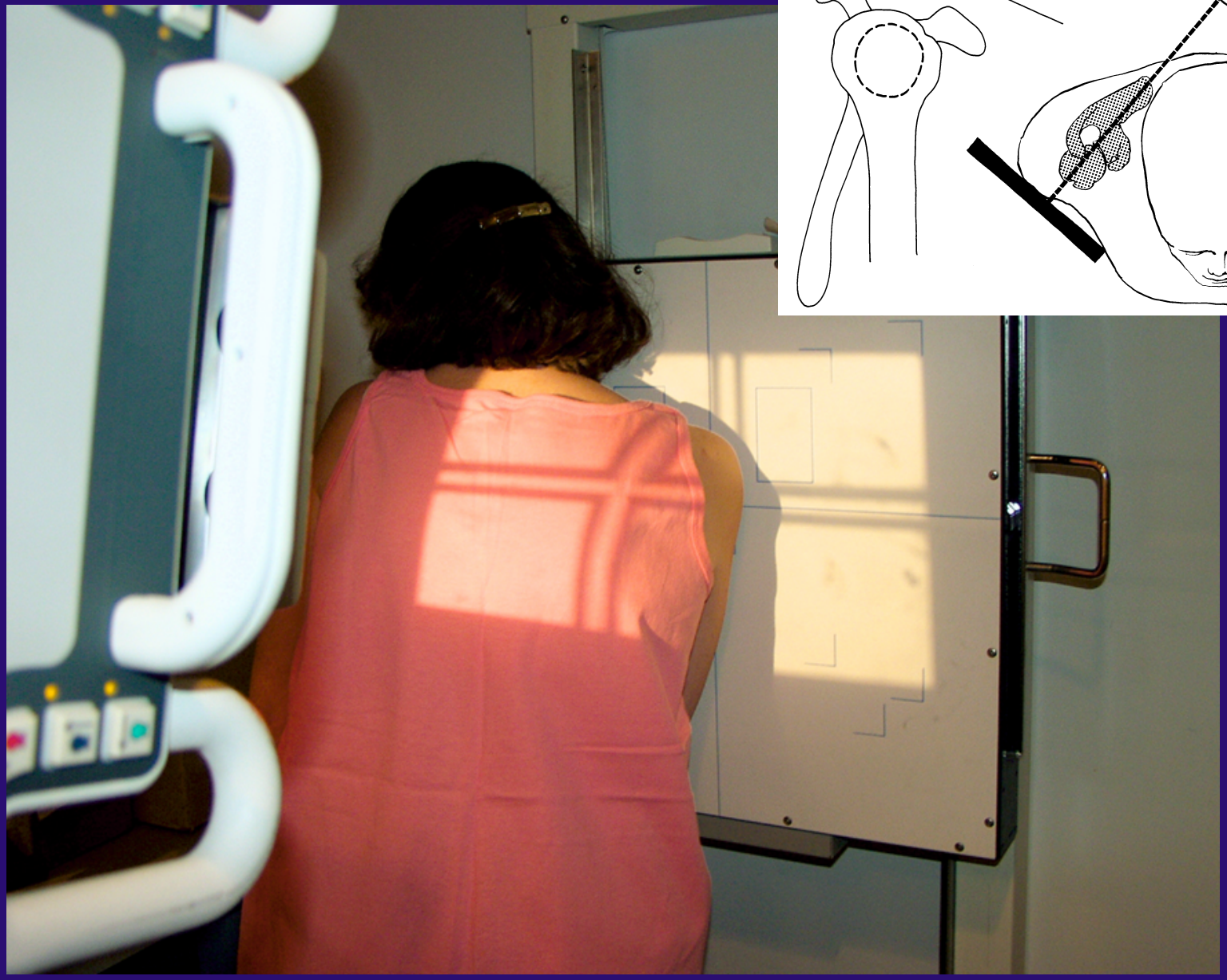

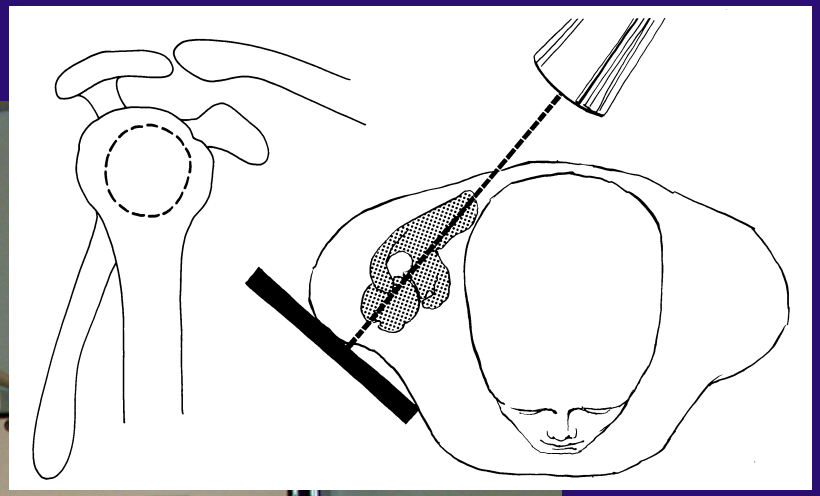

Axillary Lateral View

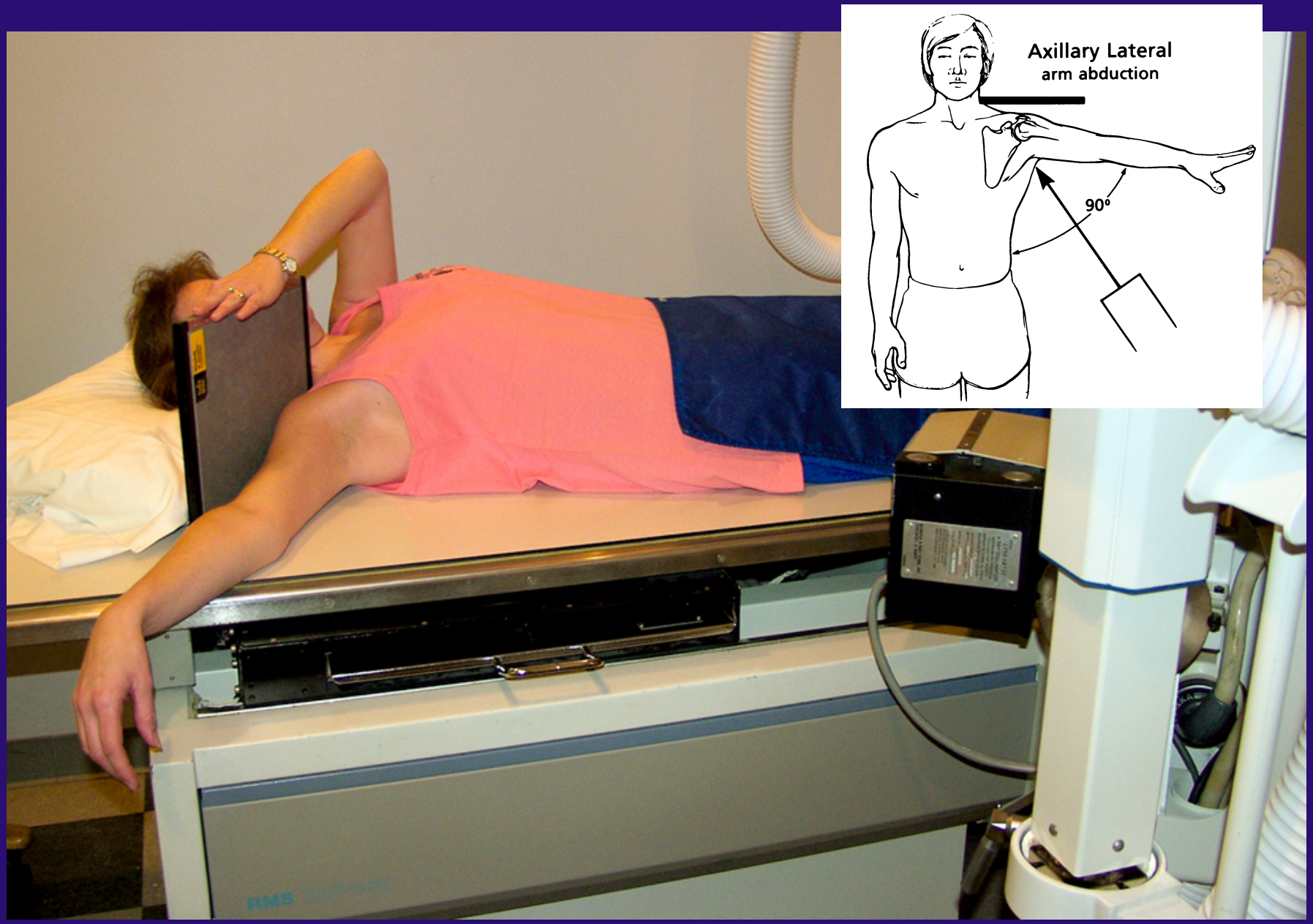

Modified Axillary View in Humeral External Rotation

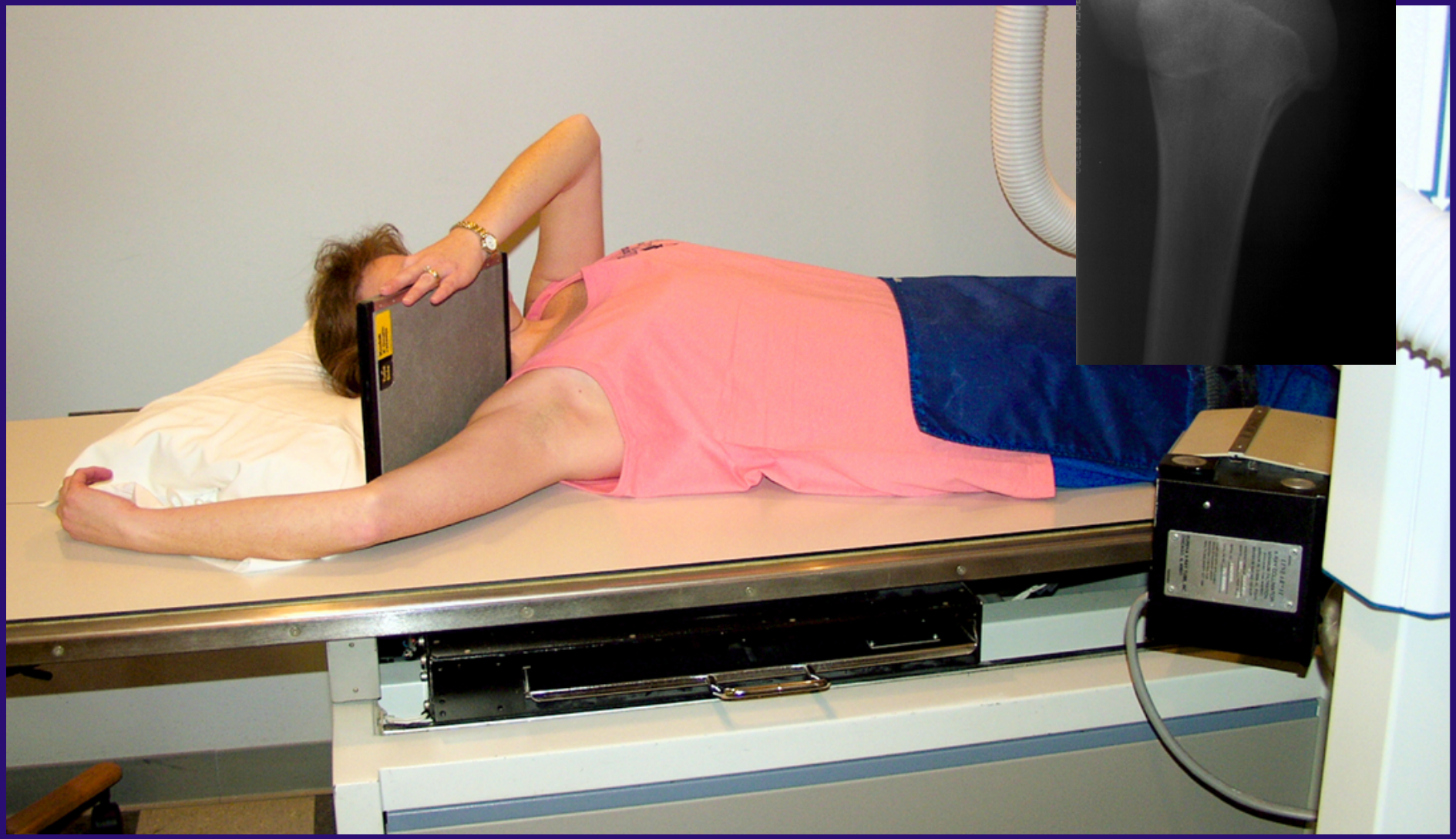

Subscapularis Muscle

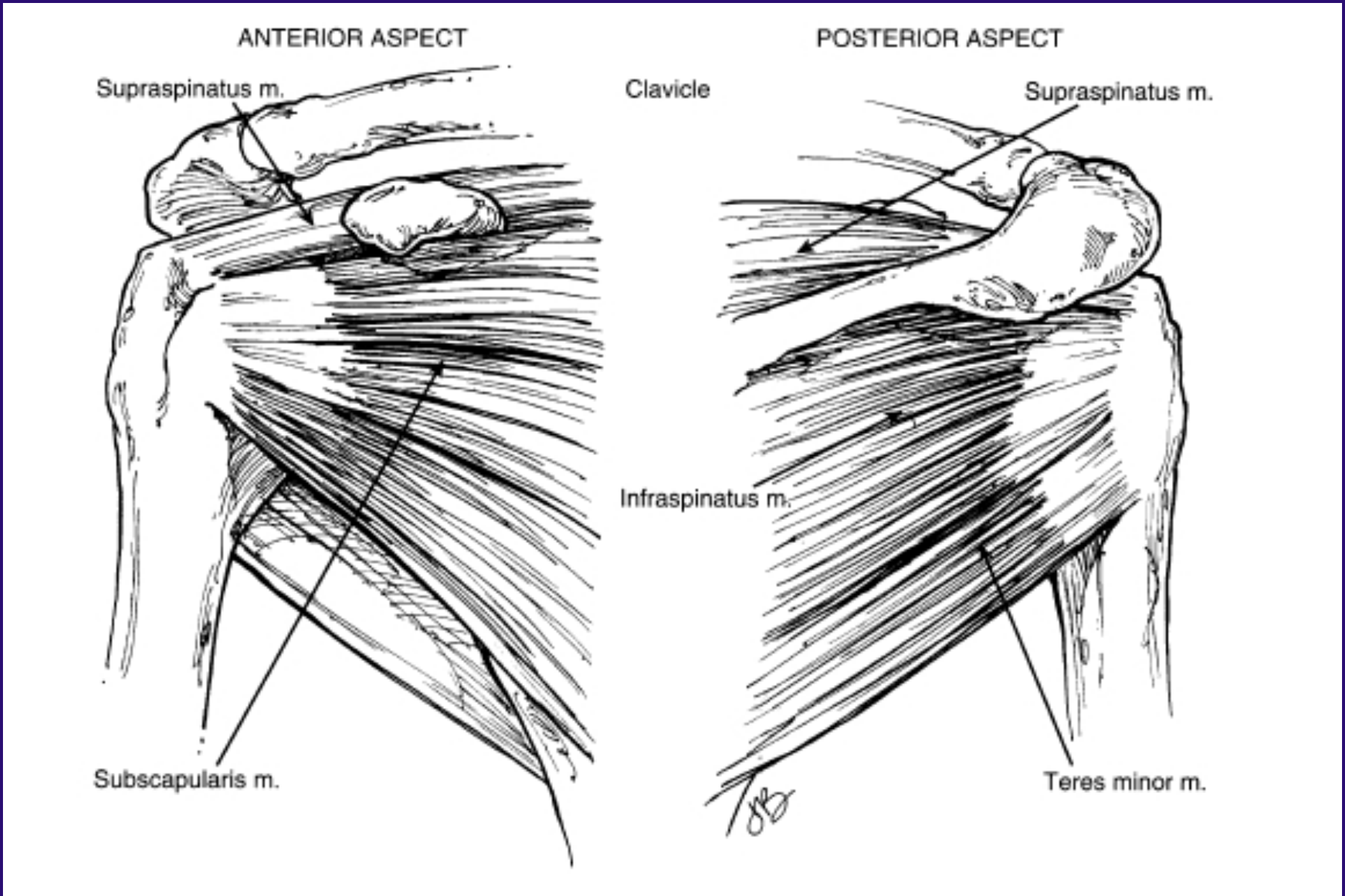

Subscapularis Tears

- Lift Off (75% tear 5-30)
  - Hand or back Lspine
  - Maximum LR
- Napoleon (50% tear)
  - Press belly, flexes wrist
- Bear Hug (Upper tear, most sensitive)
  - Hand on opposite shoulder
  - Elbow forward
  - Examiner pulls hand off shoulder

Initial Clinic Visit

- 46 year-old right-hand dominant male fell onto an outstretched right arm after tripping over his dog.
- Felt a ripping sensation in his shoulder
- Went to the emergency room, plain x-rays normal
- PE next day:
  - Pain diffusely anterior shoulder
  - Weakness, IR > ER

Clinical exam: subscapularis tear

“I was unable to get my wallet out of my back pocket.”

Subscapularis & Biceps Instability

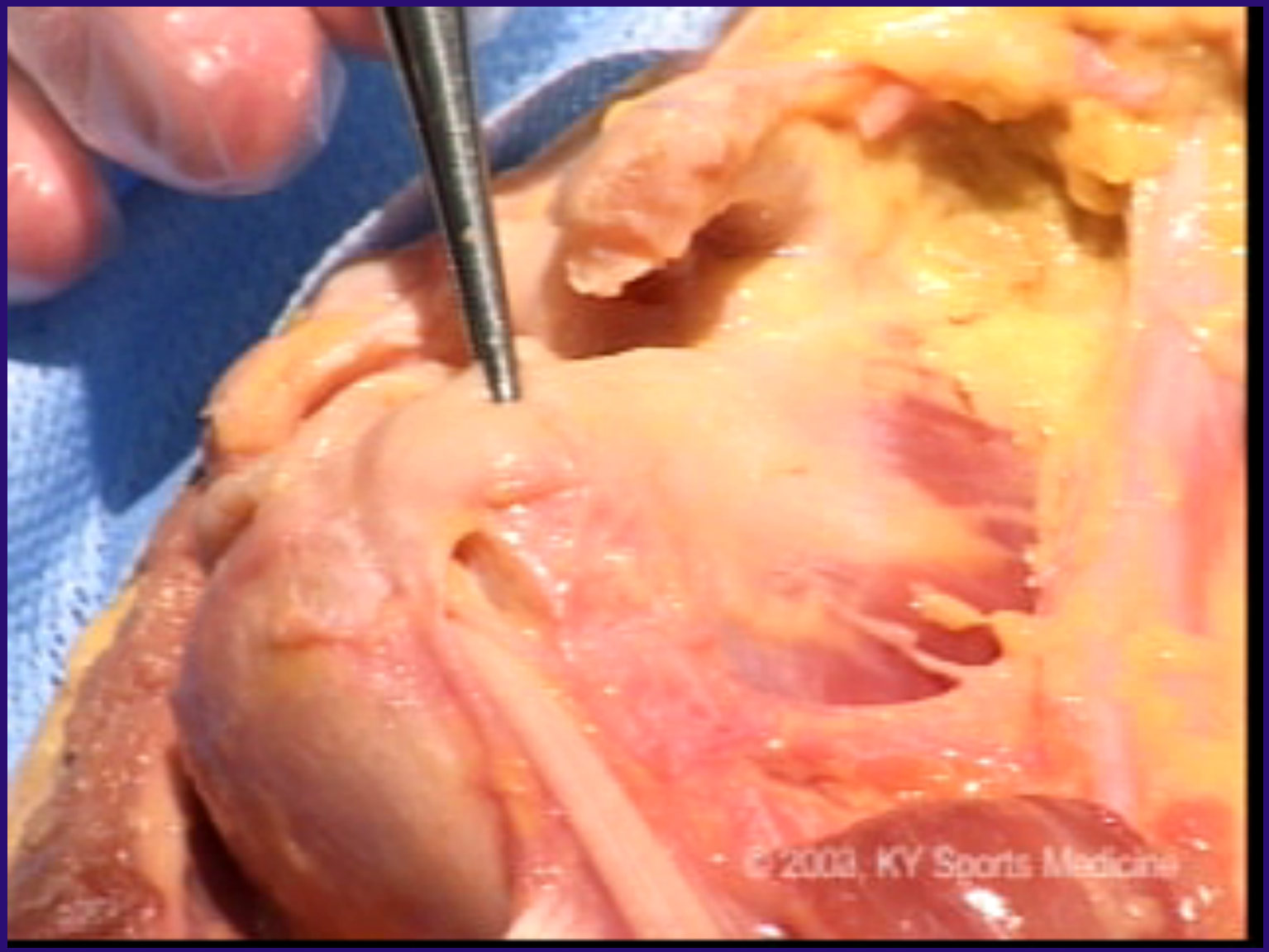

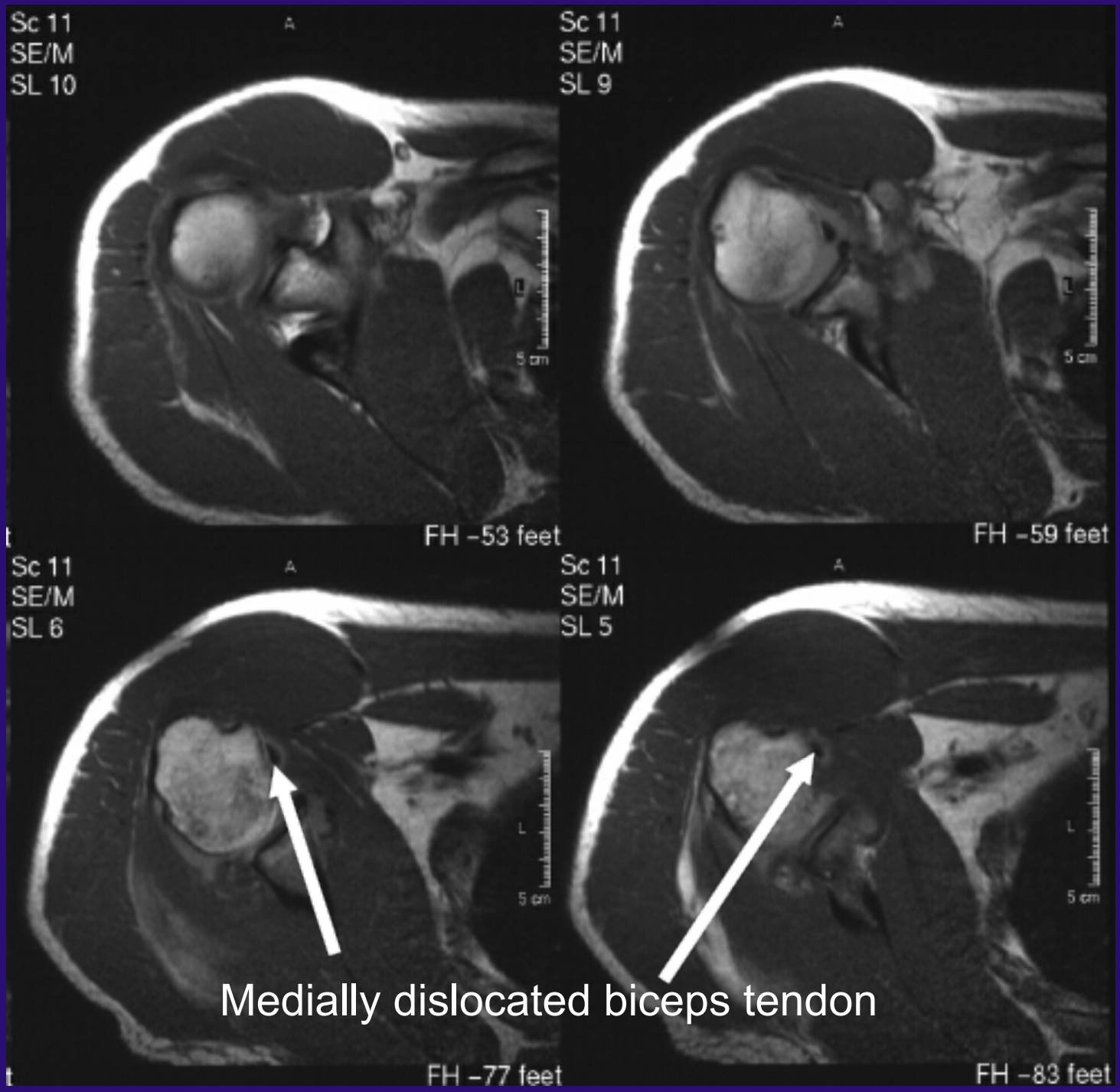
Sc 11
SE/M
SL 10
A
5 cm
FH -53 feet
Sc 11
SE/M
SL 9
A
5 cm
FH -59 feet
Sc 11
SE/M
SL 6
A
5 cm
FH -77 feet
Sc 11
SE/M
SL 5
A
5 cm
FH -83 feet
Medially dislocated biceps tendon

Biceps Tendon

- Often associated with:
  - Subscapularis tear
  - Chronic rotator cuff tears
- Presentation
  - Initial ecchymosis and pain, then feel better
- Treatment
  - Repair other associated tears
  - Tenodesis vs. tenotomy

Pectoralis Major Rupture
33 YO Male

- Bench pressing weights
- Weight amount he did ten ye
  previously
- Felt a rip, pain, deformity,
  right pectoralis

34 YO RHD weight-lifter

Pain over AC joint s/p arthroscopy labral debridement 3 years previously

Right AC osteolysis

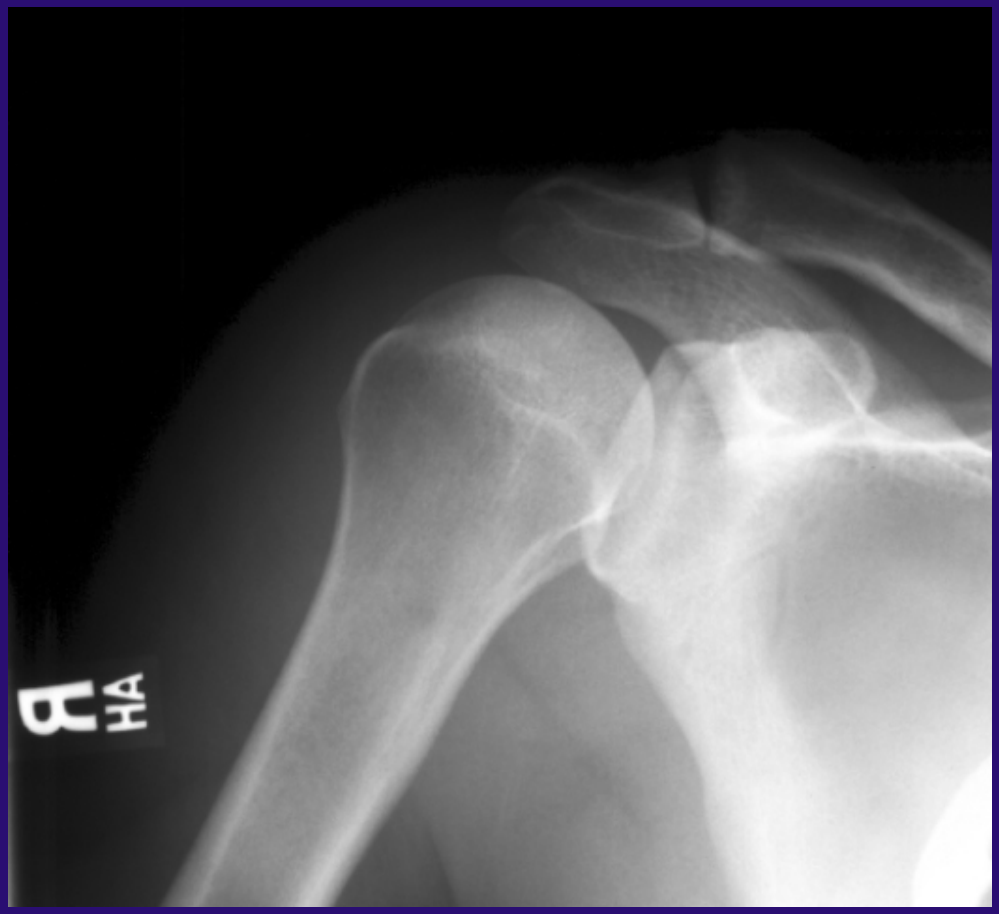

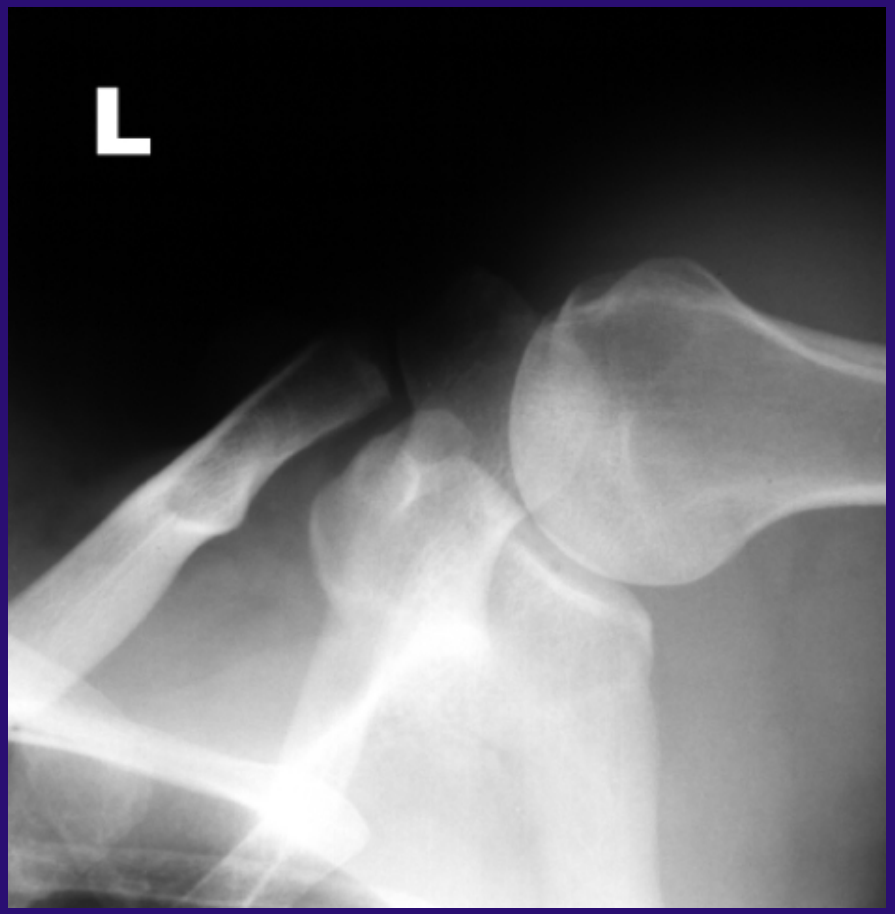
L

Open distal clavicle resection

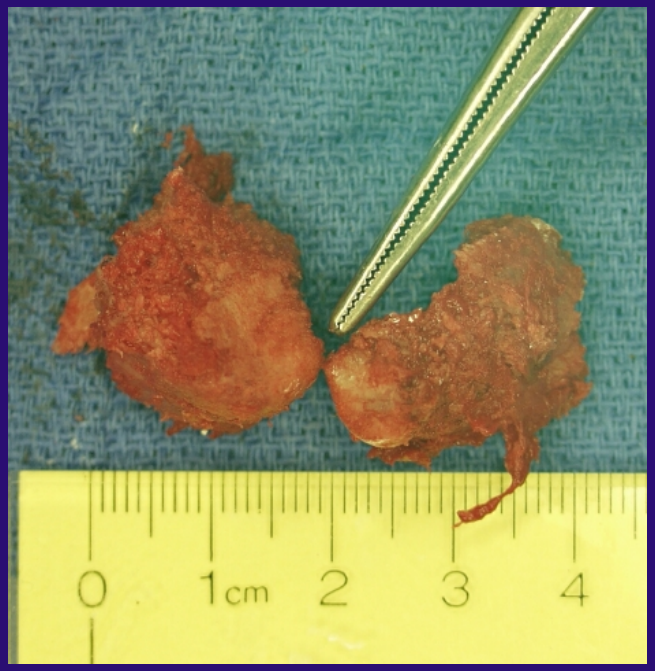

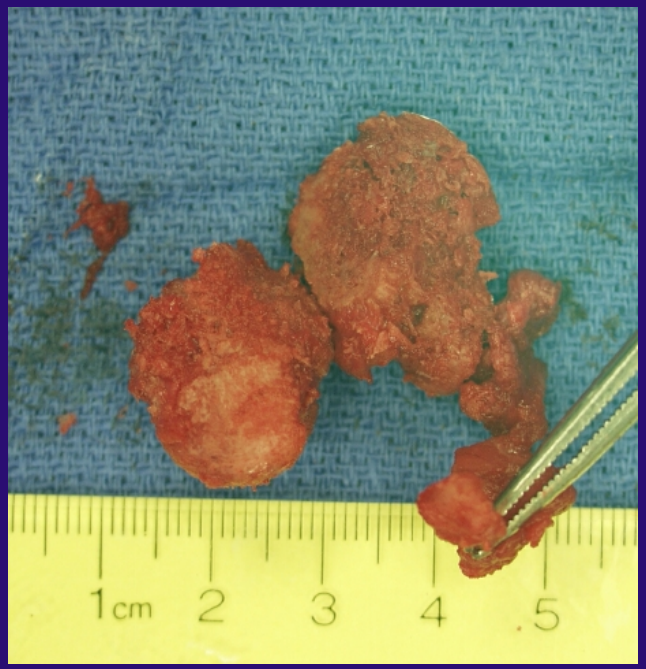

You May Not Have Seen It, But It Has Seen You

31 YO female Lawyer
Shoulder pain; don't forget the coracoid

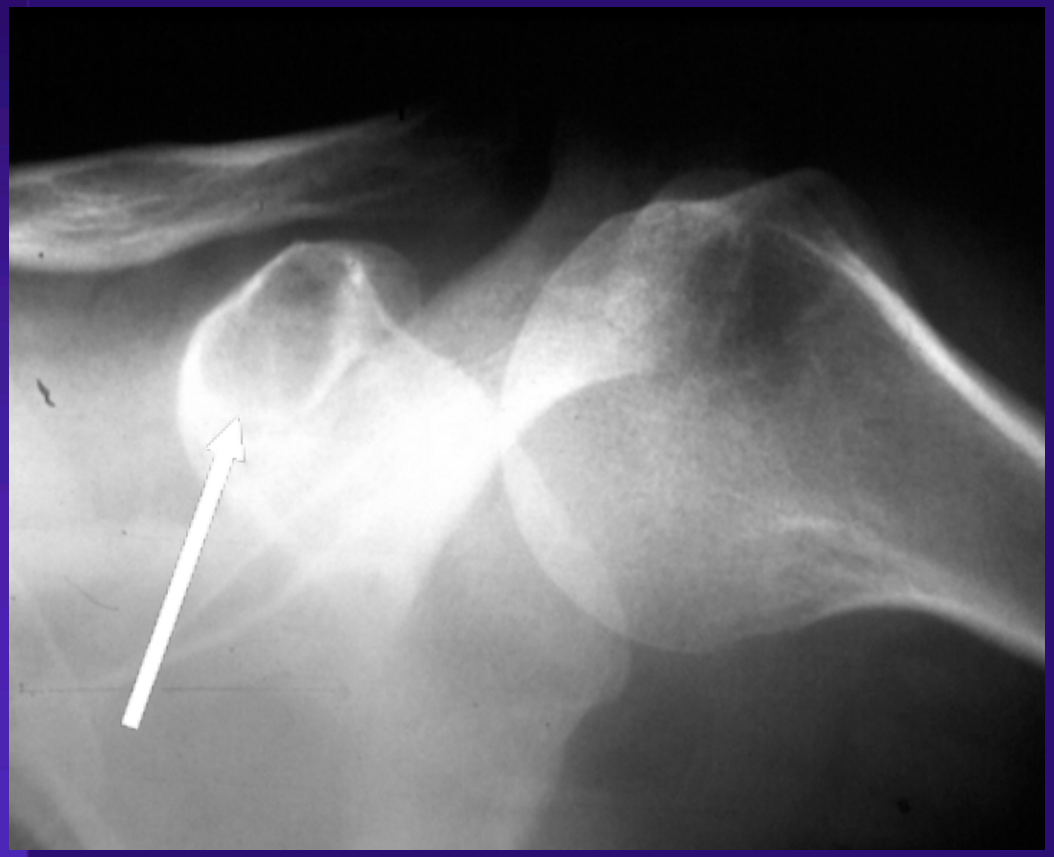

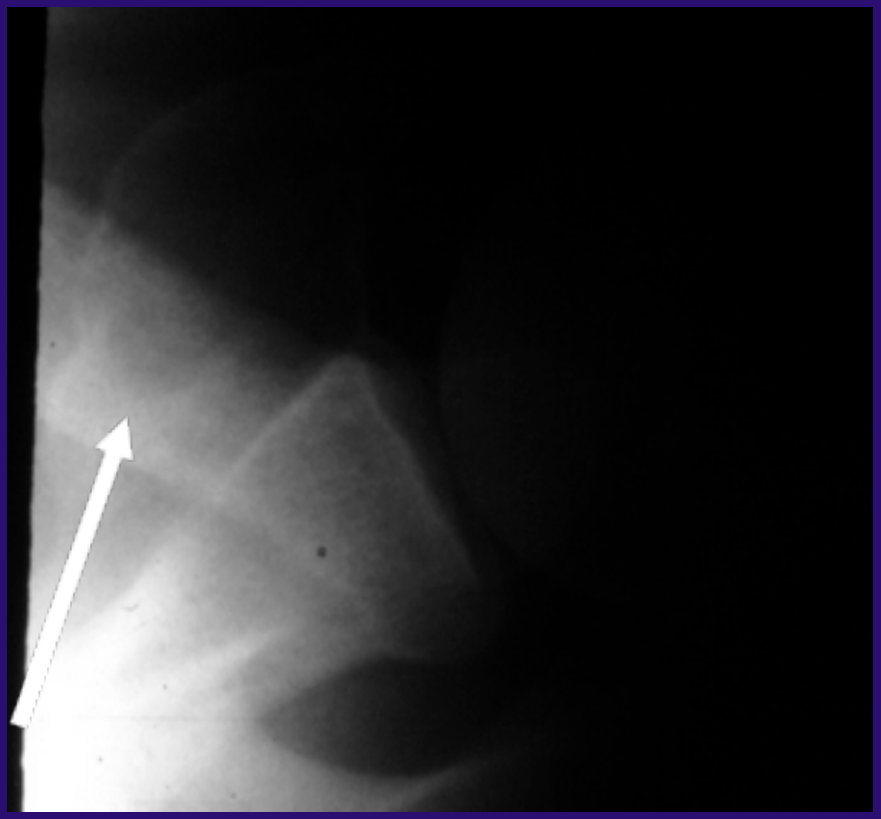

16 months later
Continued impingement signs
Remember the coracoid

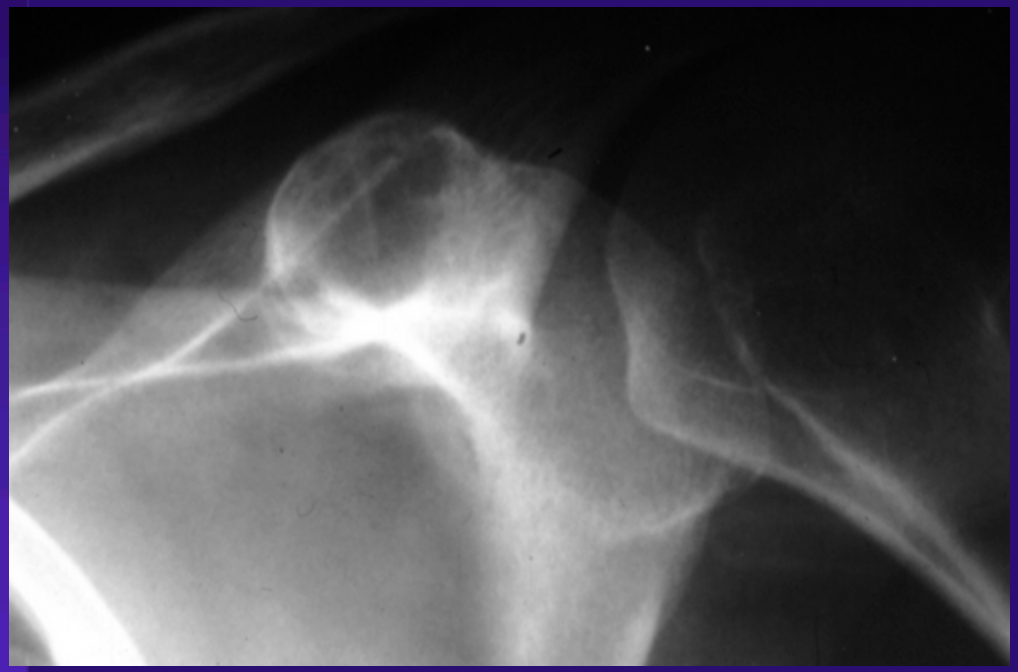

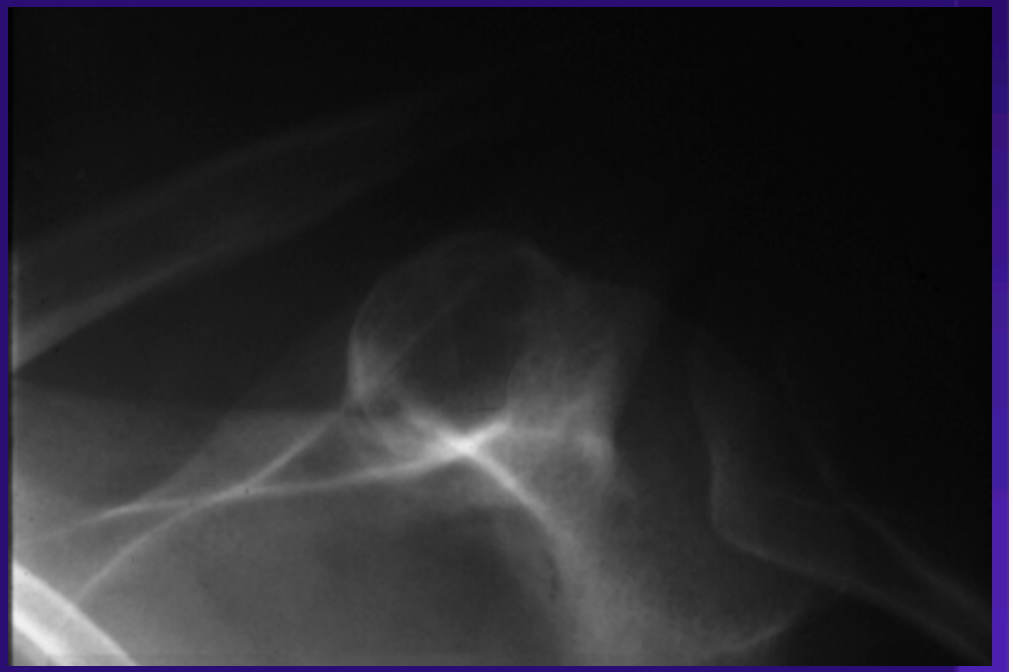


11-APR-
16:26:49

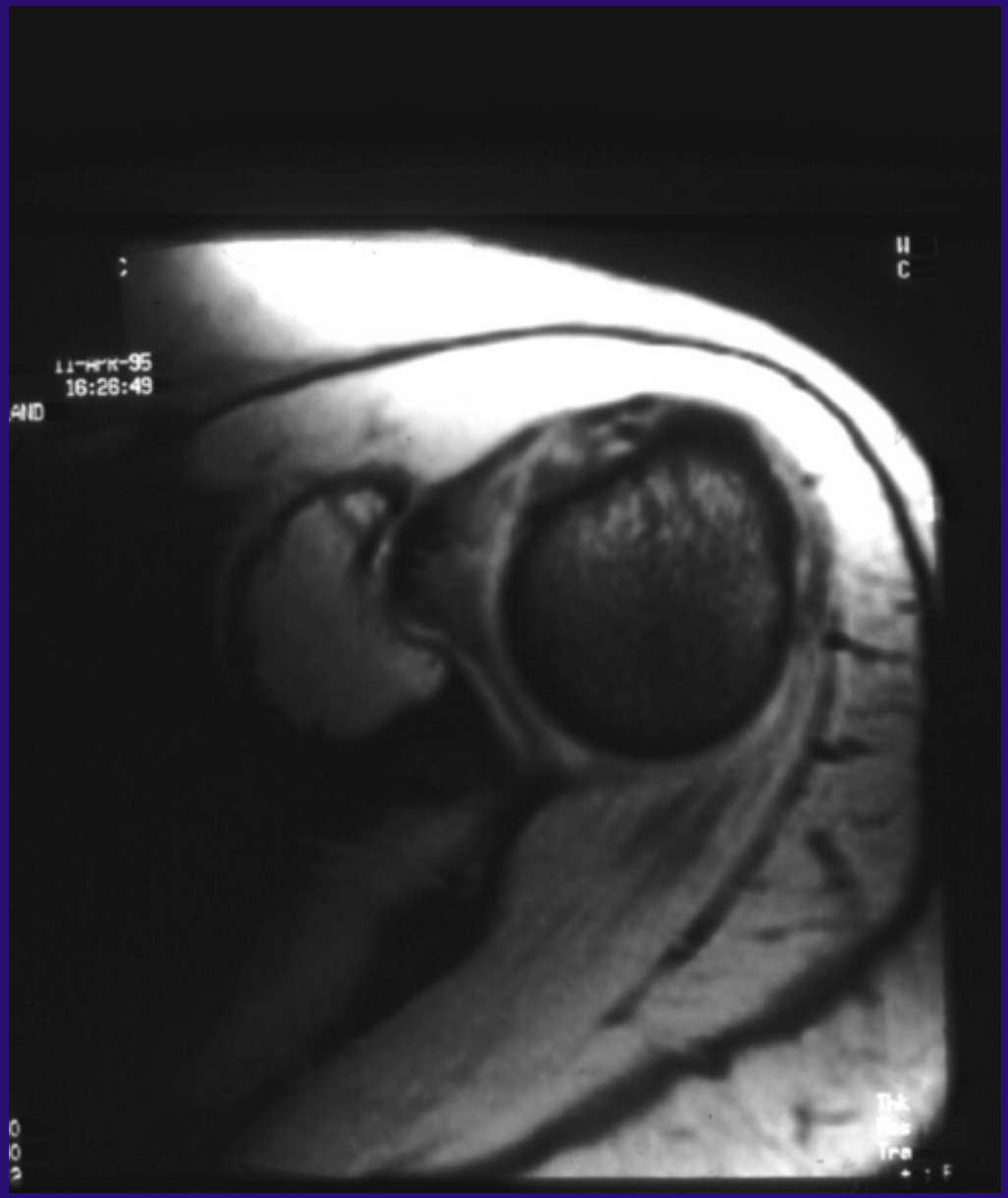
11-APR-95
16:26:49
AND

Gr. 1 Chondrosarcoma, coracoid

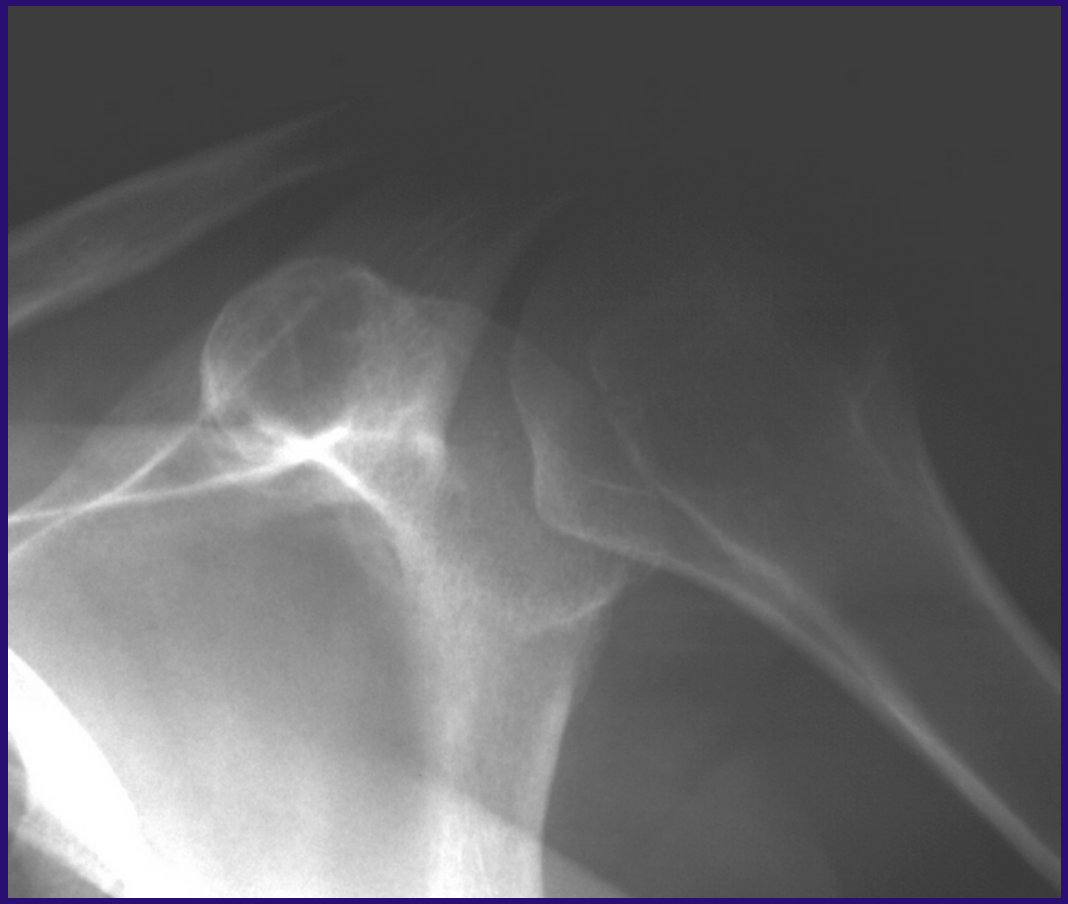

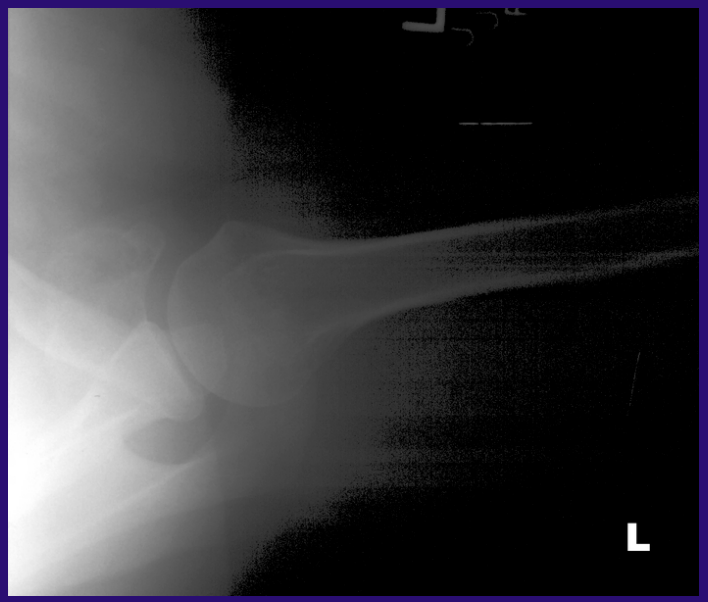

Get preop xrays; remember the coracoid!

12 YO Male Soccer Athlete

- Pain in left shoulder, 1 to 2 years
- No injury
- PE: normal stability
- Mildly tender firm axillary mass

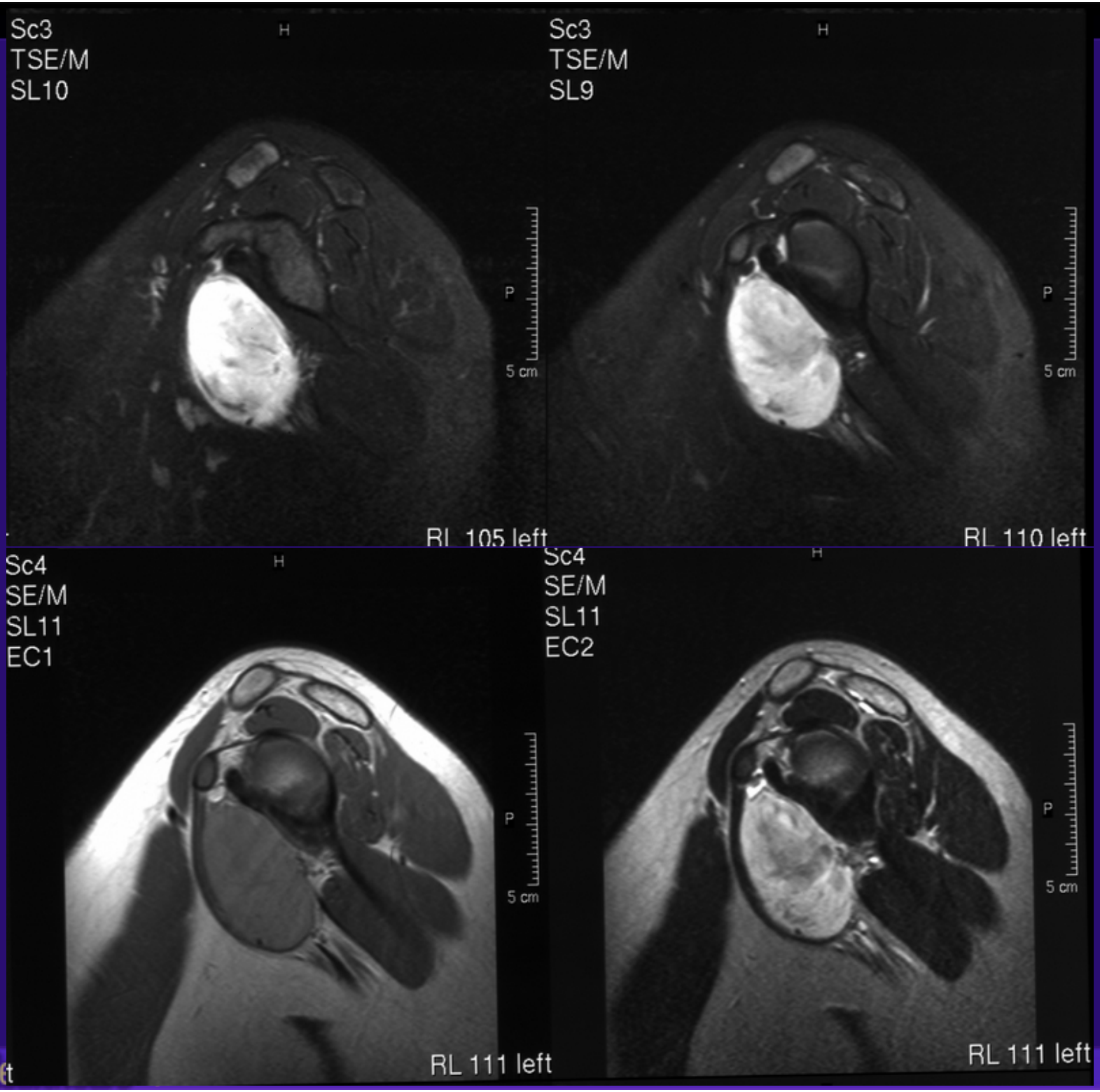
Sc3
TSE/M
SL10
H
P
5 cm
RL 105 left
Sc3
TSE/M
SL9
H
P
5 cm
RL 110 left
Sc4
SE/M
SL11
EC1
H
P
5 cm
RL 111 left
Sc4
SE/M
SL11
EC2
H
P
5 cm
RL 111 left

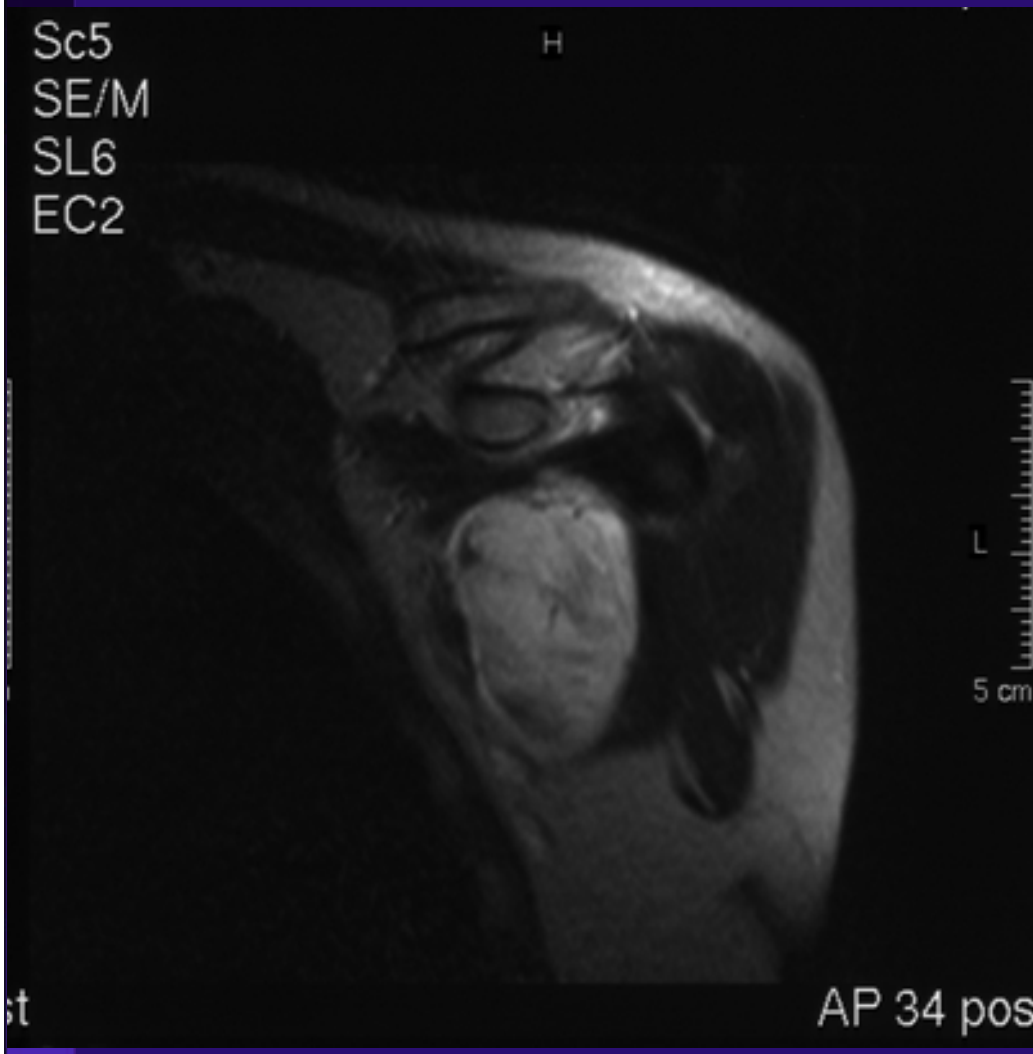
Sc5
SE/M
SL6
EC2
H
L
5 cm
AP 34 post


Sc5
SE/M
SL5
EC1
H
L
5 cm
AP 30 post

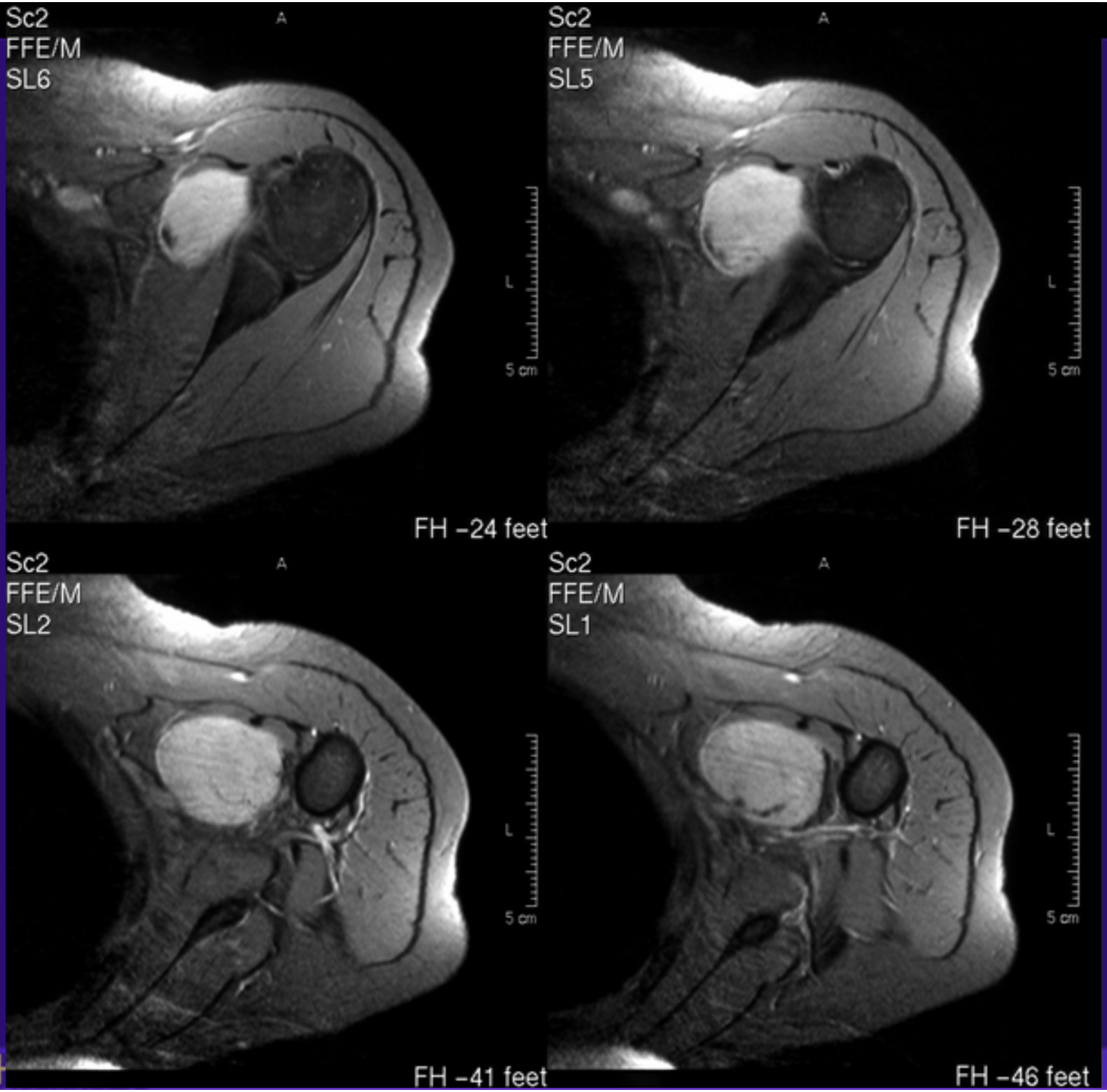
Sc2
FFE/M
SL6
A
L
5 cm
FH –24 feet
Sc2
FFE/M
SL5
A
L
5 cm
FH –28 feet
Sc2
FFE/M
SL2
A
L
5 cm
FH –41 feet
Sc2
FFE/M
SL1
A
L
5 cm
FH –46 feet

Dx: Synovial Sarcoma

- Underwent limb salvage sarcoma resection and chemotherapy

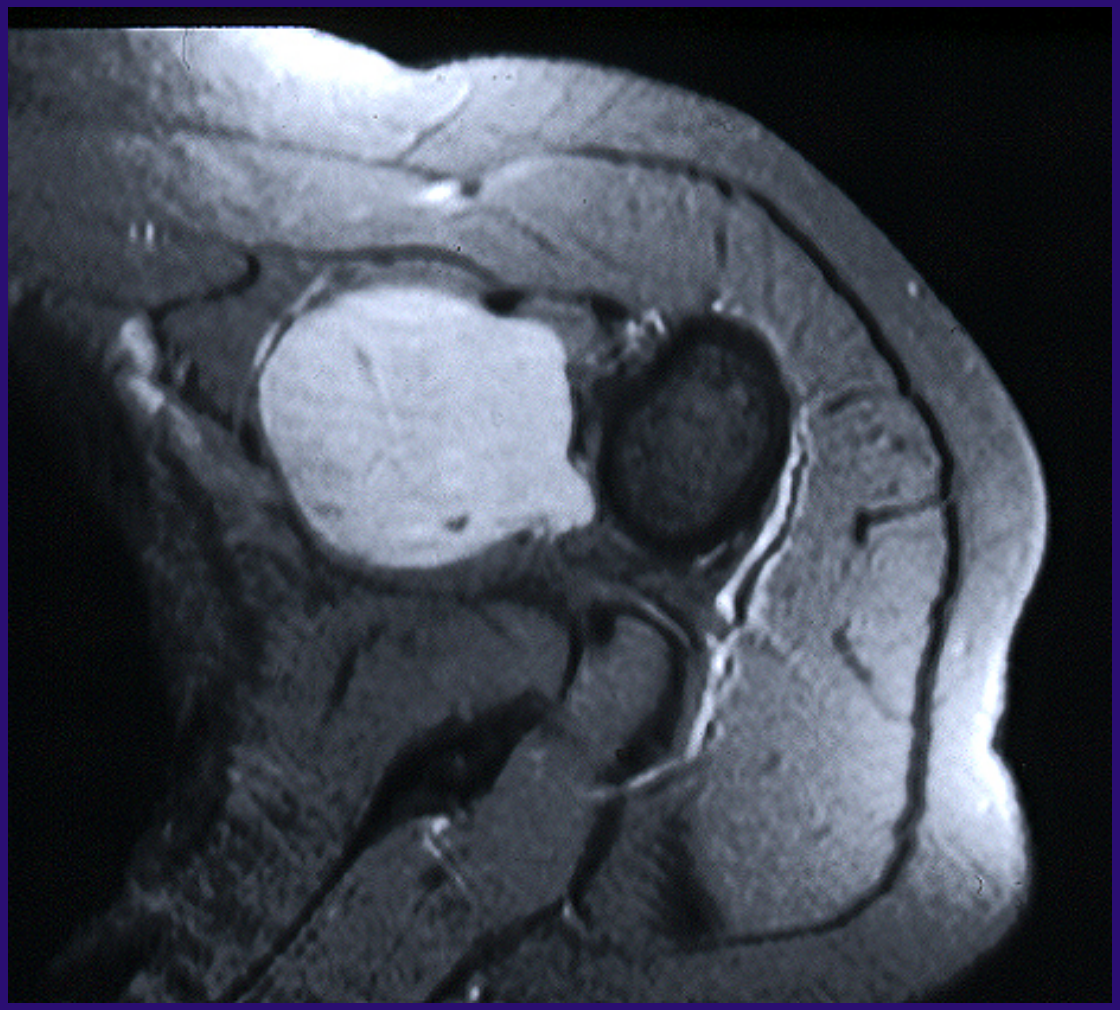

22YO LHD Male

- Multiple osteochondroma
- Girlfriend noted scapular asymmetry

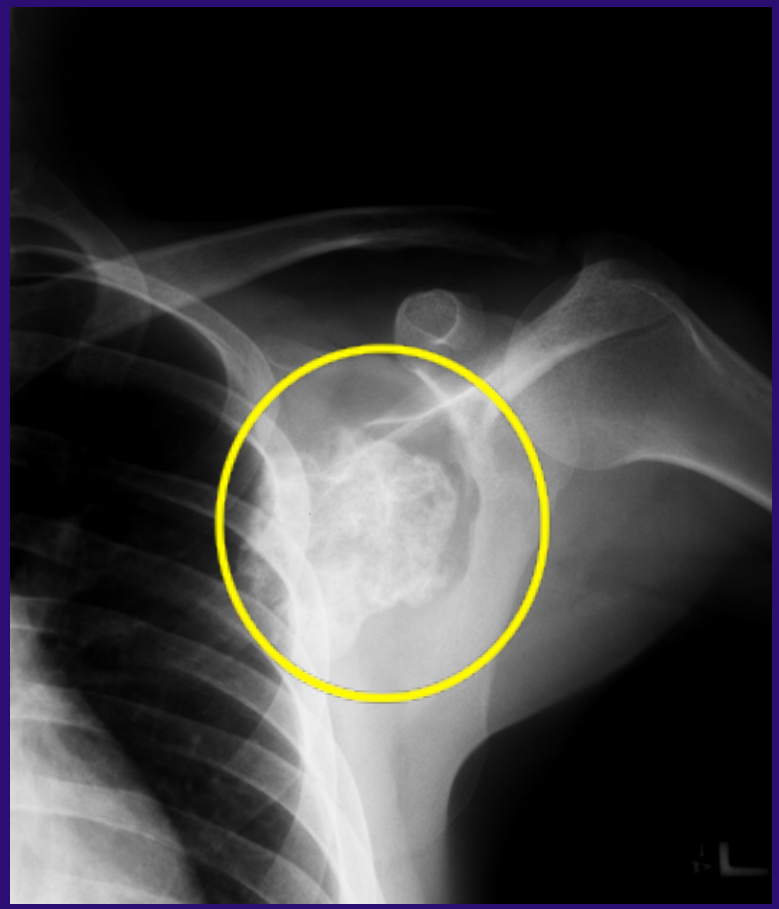

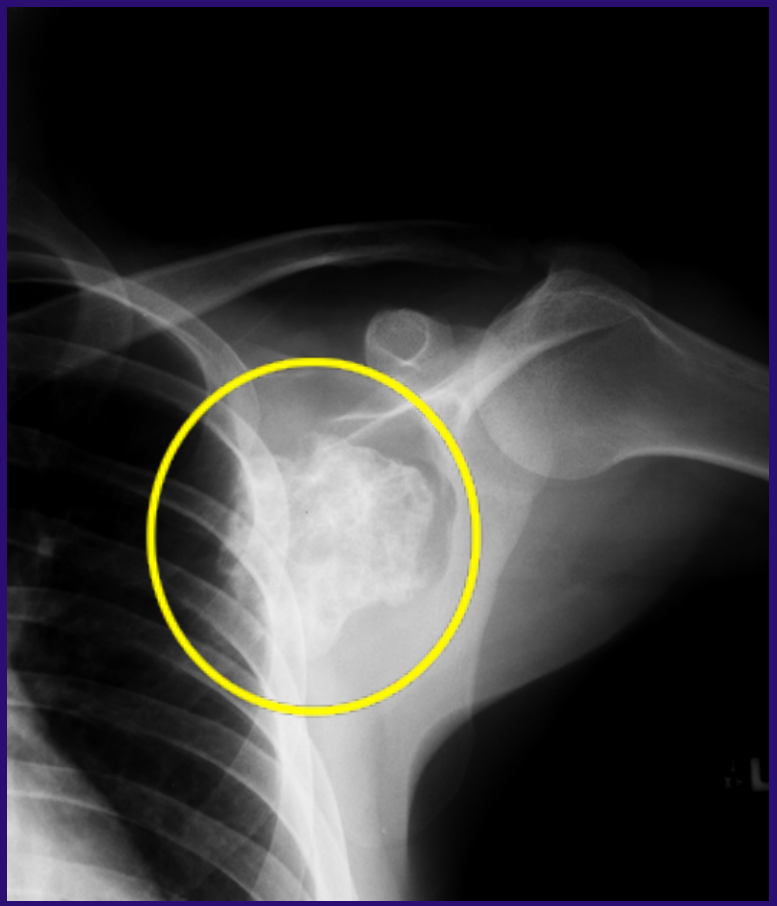

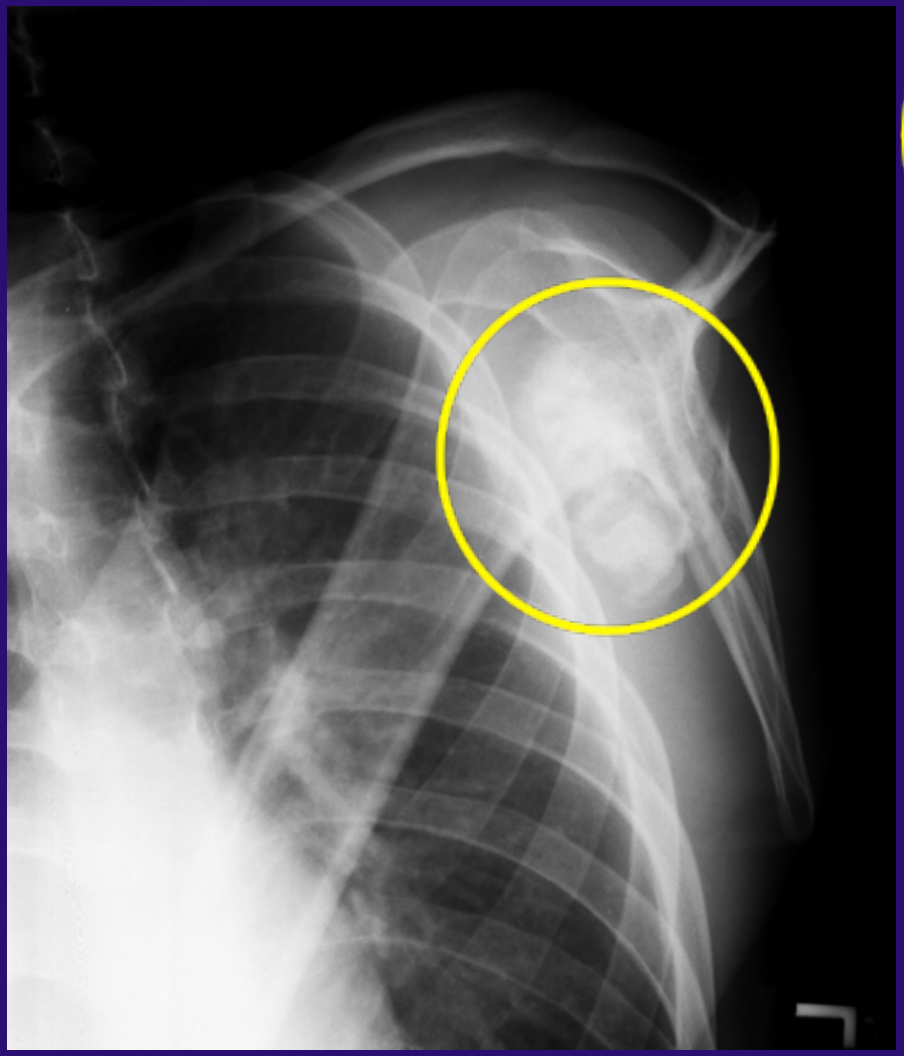

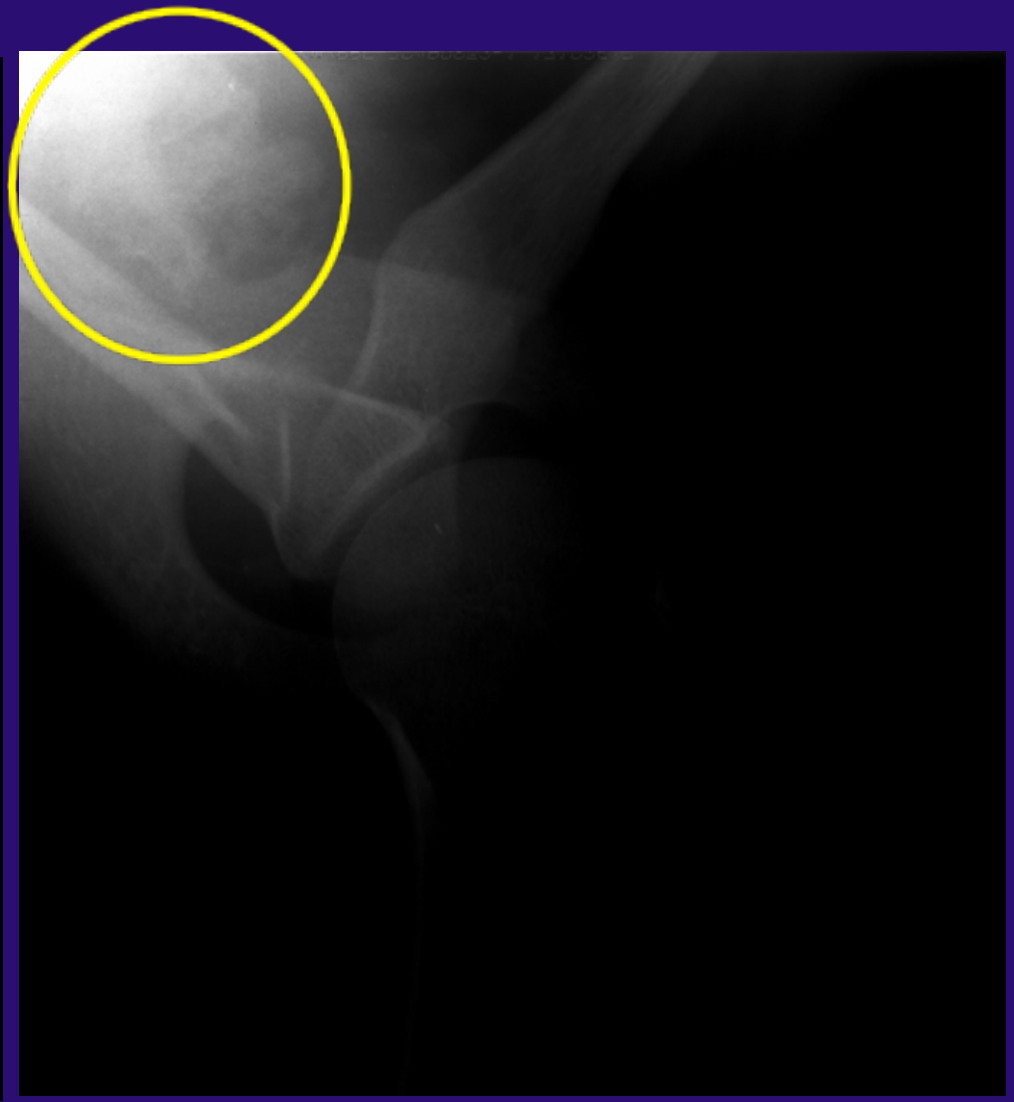

True space occupying mass

- Causing “winging” and “snapping”
- Axial skeleton osteochondroma
- Underwent resection mass
- Diagnosis: osteochondroma, no malignant change

Make the Primary Diagnosis!

Shoulder Pain Algorithm: AAOS Clinical Guideline on Shoulder Pain, in *Orthopaedic Knowledge Update: Shoulder and Elbow 2* (AAOS, 2002), p. 448-455.

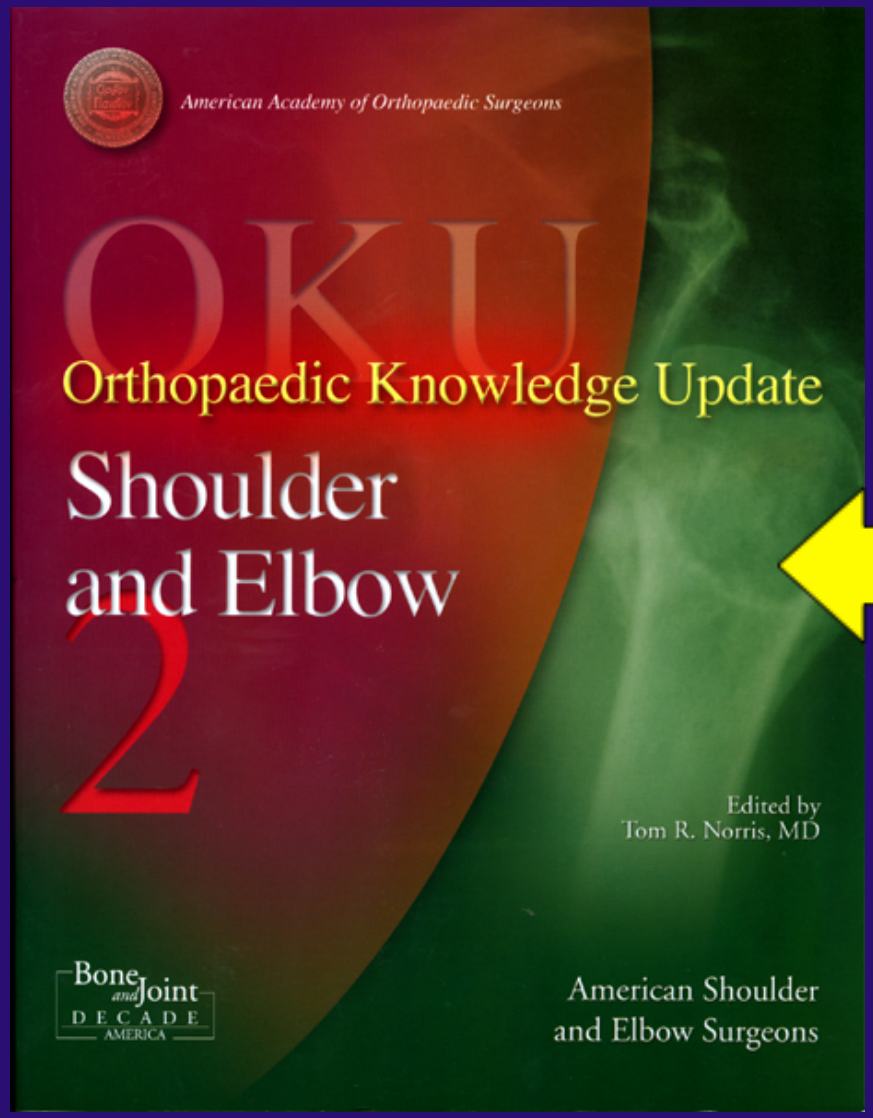

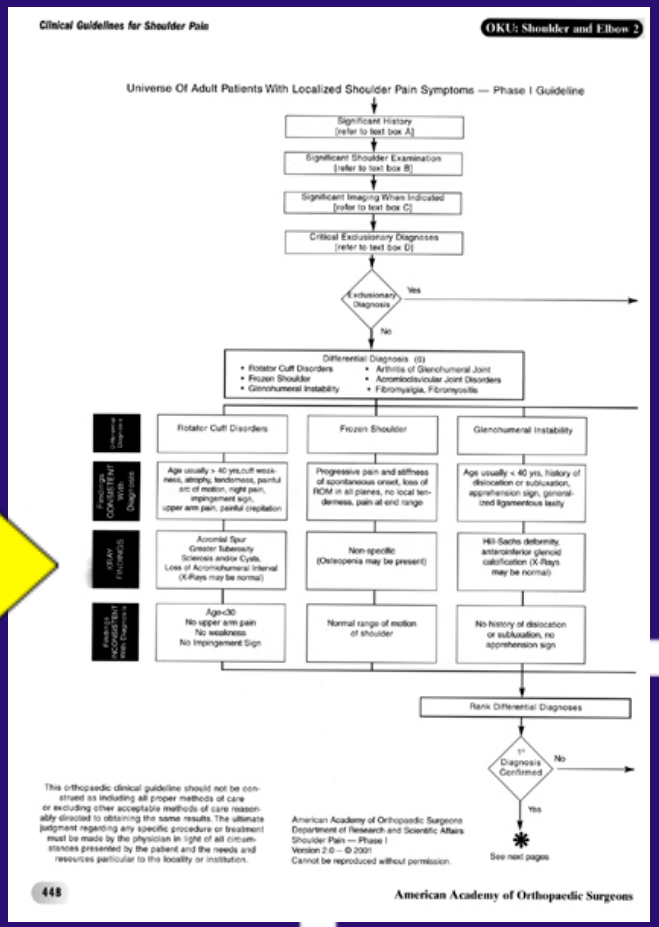

[more]

[more]

Imaging

- Special Studies
  - MRI scan
    - With or without gadolinium
  - CT scan
  - Ultrasound

Ultrasonography

- In office
- Accurate
- Low cost

Churchill RS, Fehringer EV, Dubinsky TJ, Matsen FA, "Rotator cuff ultrasonography: diagnostic capabilities," *J Am Acad Orthop Surg* 2004 Jan-Feb;12(1):6-11.

Ultrasound showing symptomatic progression of previously asymptomatic rotator cuff tear.

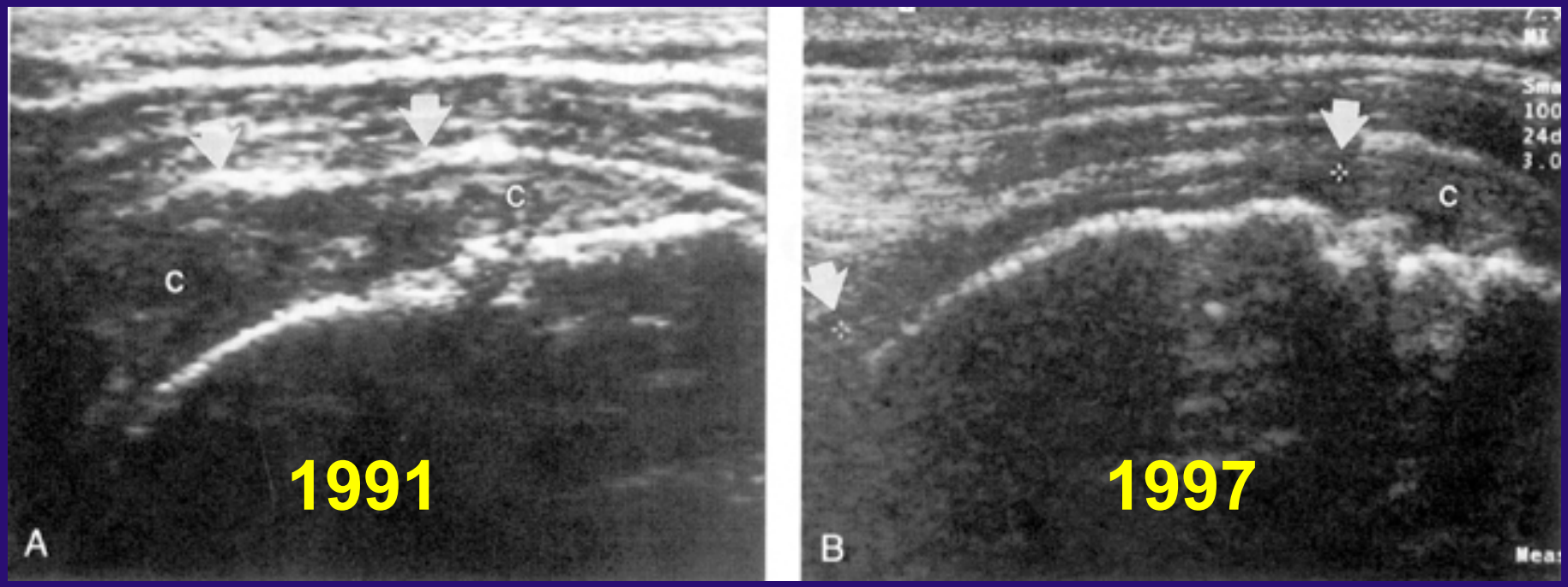

Yamaguchi K et. al., "Natural history of asymptomatic rotator cuff tears: A longitudinal analysis of asymptomatic tears detected sonographically,"
J Shoulder Elbow Surg 2001;10:199-203.

Shoulder Pain Algorithm: AAOS Clinical Guideline on Shoulder Pain, in *Orthopaedic Knowledge Update: Shoulder and Elbow 2* (AAOS, 2002), p. 448-455.

Differential Diagnosis Categories

- Rotator Cuff Disorders
- Frozen shoulder
- GH Instability
- Arthrosis
- AC Joint Disorder
- Fibromyalgia

Shoulder Pain Algorithm: AAOS Clinical Guideline on Shoulder Pain, in *Orthopaedic Knowledge Update: Shoulder and Elbow 2* (AAOS, 2002), p. 448-455.

- Needs specialized care
- Refer to specialist

  Definition of musculoskeletal specialist: licensed physician who focuses on management of musculoskeletal conditions

CONCLUSIONS

- Don't order a test if you can't read it.
- Communicate with the radiologist at your imaging center.
- A bad scan is worse than no scan.
- In KY, we have many MRI scanners. Shoulder scans are notoriously bad if ordered by someone who is unable to examine a shoulder.

CONCLUSIONS

“Sometimes an MRI report just doesn’t help. . . “

北京医科大学第三医院放射科

CT、MRI号

X 线 号

病 案 号

MRI 检查申请单

申请日期：00 年 10 月 12 日　　检查日期：0 年 月 日

姓名	汉字：孙爱	男、女	出生：00年10月12日28岁	体重 Kg
	拼音：	科室	病房床号	电话
患者永久通讯地址			邮编	电话

请注意：装有心脏起搏器的患者以及动脉瘤术后者不能作此项检查！

由临床医师逐项填写

病历摘要：

手术史：无、有（ 年 月 日 ）

临床诊断：

检查部位与要求：

体内金属：无、有（ ）

申请医师：

上海长海医院 MRI 报告单

姓名孙爱　性别女　年龄28岁　科别骨　检查部位左膝

病区 9　床号　住院号　MRI 号50666　报告日期2000.10.23

左膝关节MRI

MRI 所见：

Conclusions

- By:
  - Knowing Anatomy
  - Understanding Biomechanics
  - Sport of injury
  - Mechanism
- Physical Exam makes sense and Specific Diagnosis is made

Little League pitchers do NOT become Big League pitchers



Nolan Ryan didn't start pitching until he was in high school

Try to put the whole picture together



Treat the entire patient!

The End . . . Thank You!

QUIT