Medial and Posteromedial Structures of the Knee: An Anatomical and Functional Presentation

Robert S. Burger, MD, Jonathan Greenleaf, MD, and Stanley James, MD

Abstract

With images obtained during meticulous dissections of fresh cadaveric specimens, the authors have carefully detailed the structures of the medial and posteromedial aspects of the knee in order to review the important static and dynamic roles these structures play in knee function. Included are the confluence of the fascial slings of the pes anserinus tendons, the intricacies of the medial collateral ligament and the posterior oblique ligament, and the multiple insertions of the semimembranosus tendons. The relationship of all these structures to the medial meniscus and their importance to normal function are also outlined.

Arch Am Acad Orthop Surg 1997;1:21-29

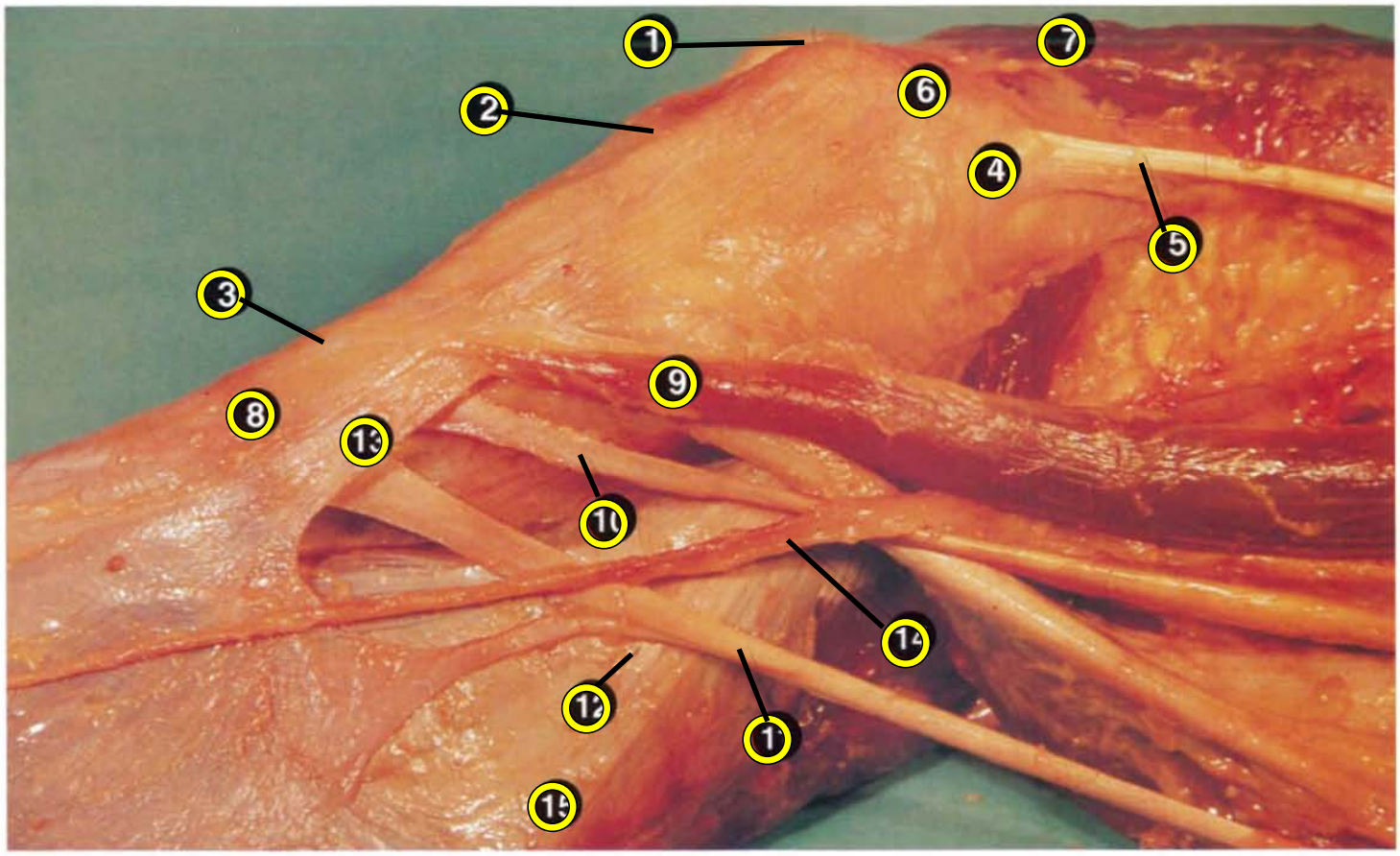

Figure 1

The structures of the medial aspect of the knee (Figs. 1–5) include the patella (1), patellar tendon (2), tibial tubercle (3), adductor tubercle (4), adductor magnus tendon (5), medial epicondyle (6), vastus medialis obliquus (7), pes anserinus (8), sartorius muscle and tendon (9), gracilis muscle and tendon (10), semitendinosus tendon (11) and expansion (12), pes conjoined tendon (13), sartorial branch of the saphenous nerve (14), gastrocnemius muscle (15), medial collateral ligament (MCL) (16), and pes anserinus bursa (17).

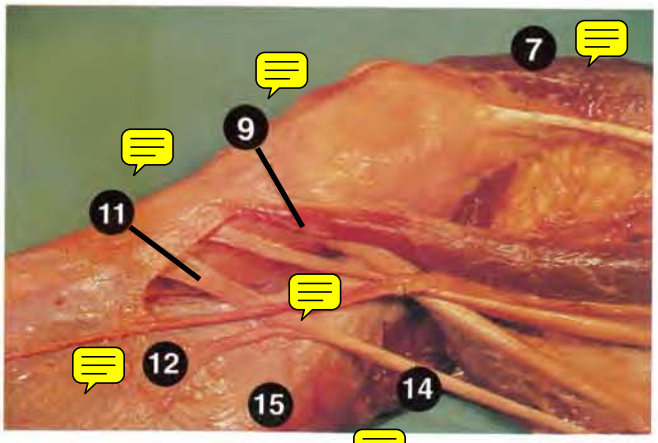

Figure

The capsule of the knee joint forms a sleeve surrounding the joint with a defect anteriorly filled in by the extensor mechanism. Medially, it is convenient to divide the anatomic structures into three segments, both from superficial to deep and from anterior to posterior.

From superficial to deep, there are three layers. Layer 1, the most superficial, includes the deep fascia (retinaculum) from the patellar tendon anteriorly to the popliteal fossa posteriorly. The pes anserinus tendons (8) are included in this layer. Our dissections begin with the pes anserinus tendons after removal of the retinaculum.

Layer 2 is composed mainly of the superficial tibial MCL. Controversy exists regarding the makeup of the MCL fibers and whether there is a true posterior triangular portion or a separate group of fibers known as the posterior oblique ligament (POL). We consider the POL to be a separate anatomic and functional unit. During dissections, it becomes obvious that these structures are anatomically and functionally blended.

Layer 3 is composed of the deep medial capsular ligament, with its meniscotibial and meniscofemoral components. Posteriorly, layers 2 and 3 are almost indistinguishable; the blending of these layers creates the POL.

From anterior to posterior, we divide the medial structures into three segments. The anterior segment extends from the medial border of the patellar tendon (2) posteriorly to the anterior edge of the superficial MCL (16) and includes the anteromedial retinaculum and joint capsule. The middle segment consists of the superficial MCL and the deep capsular ligament (deep tibial MCL). The posterior segment extends from behind the superficial MCL to blend with the posterior medial capsule and forms a sling about the medial femoral condyle.

With the skin and fat and portions of the superficial medial retinaculum removed, one can see the pes anserinus complex (Figs. 1, 2). The three medial hamstring muscles—sartorius (9), gracilis (10), and semitendinosus (11)—sweep across the knee from the anteromedial thigh and join in a tendon that inserts onto the medial aspect of the tibia just anterior to the insertion of the superficial MCL, forming the pes anserinus (8).

The most superior musculotendinous unit is the sartorius. Its muscle belly extends the most distally of the three medial hamstring muscles. The sartorius tendon may be used for reconstructive procedures for chronic and (rarely) acute medial instability. The semitendinosus tendon is more commonly used alone or in combination with the gracilis tendon for cruciate ligament reconstructions.

The pes anserinus is primarily a flexor of the knee and an internal rotator of the tibia and dynamically resists valgus and external rotational forces applied to the knee joint. The pes anserinus–plasty procedure, originally described by Slocum, releases the lower two thirds of the pes anserinus from its tibial insertion site and reflects it proximally so that the semitendinosus tendon lies just under the proximal flare of the tibia, enhancing its internal rotatory effect on the tibia to help resist abnormal rotatory motion.

When harvesting the semitendinosus or gracilis tendon for a cruciate ligament reconstruction, certain anatomic points are noteworthy (Fig. 3). The tendinous complex is usually palpable through the skin approximately three finger widths below the anteromedial joint line and 1 cm medial to the tibial tubercle. A 3-cm longitudinal incision is made. Dissecting the skin and subcutaneous tissues in all directions exposes the pes conjoined tendinous complex (13).

The tendons combine to form a veil (Fig. 4), which makes it hard to differentiate them. One must be careful to incise the outer veil in line with the tendons. The semitendinosus (11) lies at the bottom of the pes anserinus complex, and one or more tendinous expansions (12) are attached to the gastrocnemius muscle (15) (Figs. 1–3). Before sliding a tendon stripper blindly in a proximo-medial direction, it is advisable to release these expansions under direct vision.

The gracilis (10) lies slightly behind and beneath the sartorius tendon (9) (Figs. 4, 5). Before sliding the tendon stripper, make sure to lift the lower surface of the sartorius tendon. There may be tendinous expansions from the gracilis tendon as well. The large sartorial branch of the saphenous nerve enters the superficial layers between the sartorius muscle and the gracilis tendon and courses over the semitendinosus tendon distally. Pass the tendon stripper slowly to minimize injury to this structure.

When doing a medial meniscal repair, keeping the knee flexed allows the pes tendons to fall posterior and distal to the joint line (Fig. 2). Placement of retractors in front of the gastrocnemius musculotendinous complex and the pes complex protects the sartorial branch of the saphenous nerve, the greater saphenous vein, and the posterior neurovascular structures.

The pes anserinus bursa (17) is located 3 to 4 cm distal to the medial joint line and lies between the distal portion of the superficial MCL and the pes anserinus tendons (Fig. 5). This bursa can cause symptoms that must be differentiated from those of a medial meniscal tear, semimembranosus–tibial collateral ligament bursitis, or semimembranosus tendinitis.

Note the proximity of the vastus medialis obliquus muscle (7) to the adductor magnus tendon insertion at the adductor tubercle and the expansions it sends to the medial epicondyle (insertion site of the superficial MCL)(Figs. 1, 2). Some hypothesize that the vastus medialis obliquus has a dynamic effect on tensioning the MCL. Note also how the pes complex drapes over the superficial MCL, which blends into the periosteum of the tibia (Figs. 4, 5).

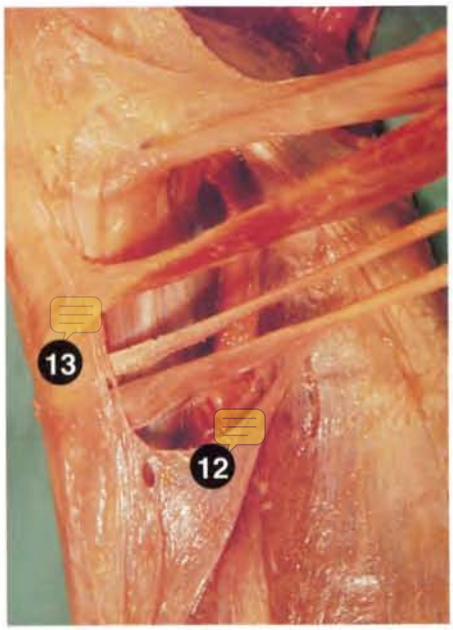

Figure 3

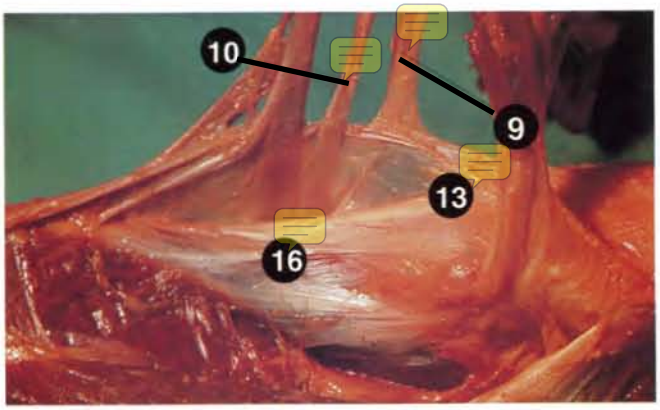

Figure 4

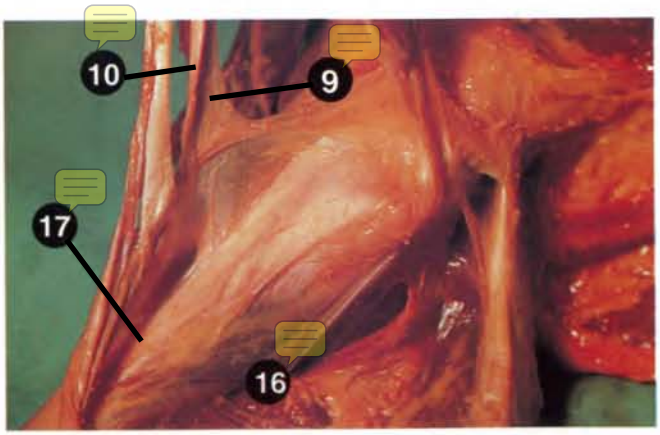

Figure 5

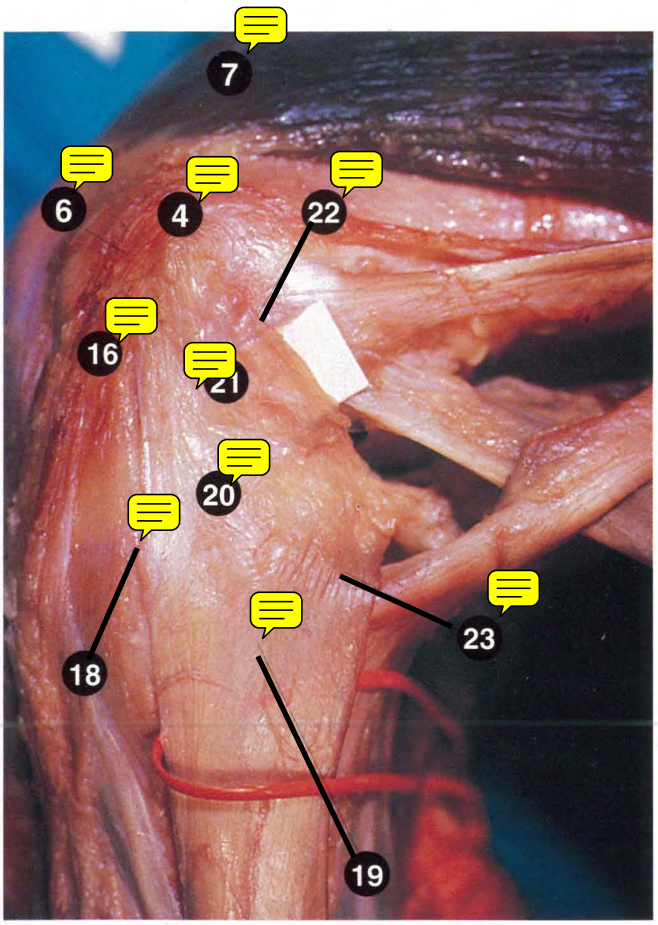

Figure 6

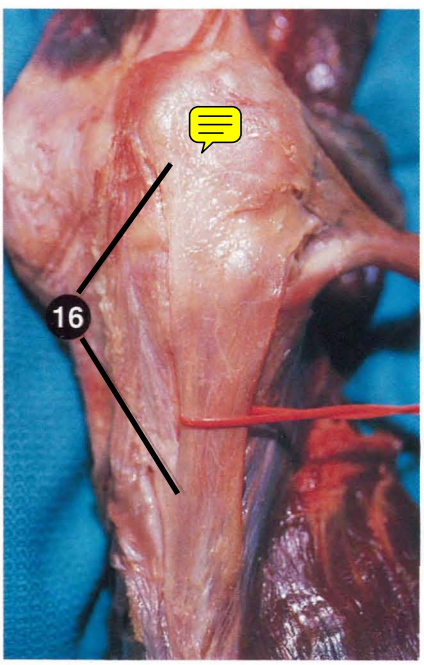

Figure 7

There are basically three structures that constitute the MCL complex: the MCL itself (16), composed of anterior parallel fibers (18), posterior inferior oblique fibers (19), and posterior superior oblique fibers (20); the POL (21), composed of the superior (capsular) arm (22), inferior (distal) arm (23), and central (tibial) arm (24); and the medial capsular ligament (25), composed of the meniscofemoral ligament (26) and meniscotibial ligament (27). Also in the region of the MCL complex is a recently described ligamentous structure designated the posterior tibial oblique ligament (28), as well as the vastus medialis obliquus (7), the medial epicondyle (6), and the adductor tubercle (4).

The MCL is also referred to as the superficial medial collateral ligament, the tibial collateral ligament, the superficial tibial collateral ligament, the superficial medial ligament, and the internal lateral ligament. The POL is also referred to as the oblique portion of the tibial collateral ligament, the posterior portion of the tibial collateral ligament, the oblique or posterior portion of the superficial tibial collateral ligament, the superior oblique fibers of the tibial collateral ligament, and the superomedial ligament. The medial capsular ligament is also referred to as the deep medial collateral ligament, the deep medial ligament, the short internal lateral ligament, and the deep tibial collateral ligament.

The MCL (16) is a broad, thick band with a broad-based origin at the medial femoral epicondyle (Figs. 6, 7). Its origin is approximately 1 cm anterior and distal to the adductor tubercle (the site of origin of the POL). It courses distally to insert approximately 8 to 10 cm below the joint line on the anteromedial aspect of the tibia below the pes anserinus tendons, where it blends in with the periosteum of the tibia.

The anterior border of the MCL is sharply delineated, with long parallel fibers, and is often palpable subcutaneously. The more posterior fibers course obliquely, both superiorly and inferiorly (Figs. 6, 8). These oblique fibers blend into the

POL. It is often difficult to differentiate some of the posterior oblique fibers of the MCL from the POL. Many authors believe this is because these are the same structure; however, we agree with Hughston that they can be delineated, at least in part, as separate structures.

The POL is a thickening of the capsular ligament that courses obliquely and posteriorly from its femoral origin at the adductor tubercle to both the posteromedial corner of the tibia and the posterior part of the capsule (Figs. 6, 8-11). The distal attachment of the POL is composed of three arms: superior, inferior, and central. The superior arm (22) is continuous with the posterior capsule and joins with the semimembranosus expansion to help form the proximal part of the oblique popliteal ligament (Figs. 8, 9, 14). The poorly defined inferior arm (23) attaches distally both to the sheath covering the semimembranosus tendon and to the tibia just distal to the direct insertion of the semimembranosus tendon (Figs. 6, 8, 9, 11). This arm is considered to be functionally insignificant.

Figure 10 shows the prominent central arm (24) by itself, with the superior and inferior arms removed. Notice its origin from the adductor tubercle, its direct attachment to the medial meniscus, and its attachment below the articular surface (but above the direct limb of the semimembranosus) to the posteromedial tibia.

Figure 11 shows the trailing edge of the central arm of the POL (24). (The superior arm has been removed, but the inferior arm is still in place.) Notice in Figures 6 and 8 the difficulty in delineating the inferior arm of the POL (23) and the posterior oblique fibers of the MCL (19).

In a recent publication, Strobel proposed a new ligamentous structure called the posterior tibial oblique ligament (28)(Fig. 8). This is formed by the posterior inferior fibers of the MCL and winds over the top of the semimembranosus tendon from below. The function of this proposed ligament has yet to be defined.

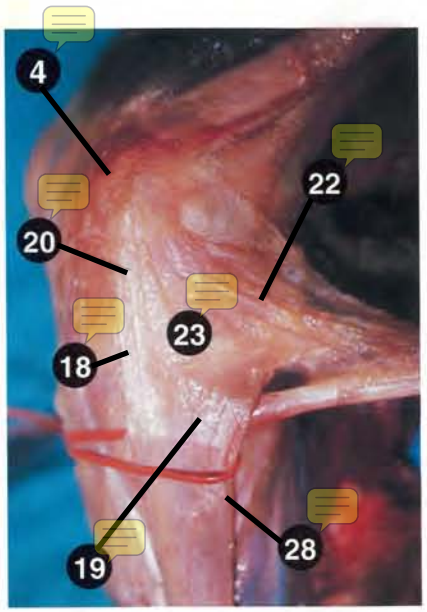

Figure 8

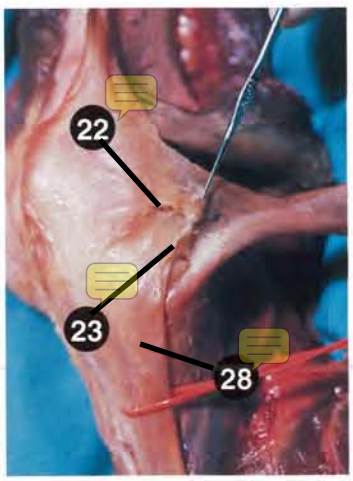

Figure 9

Figure 10

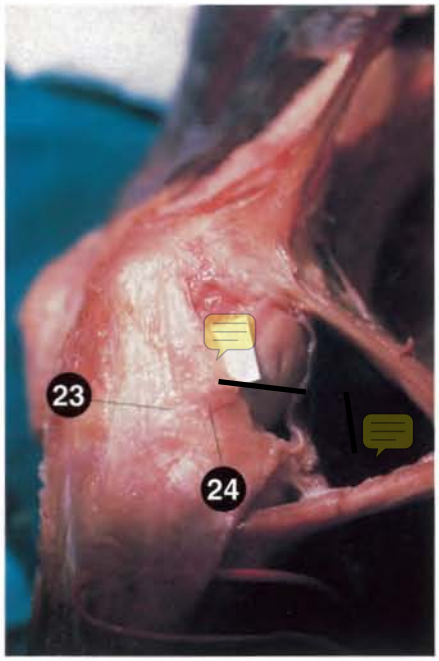

Figure 11

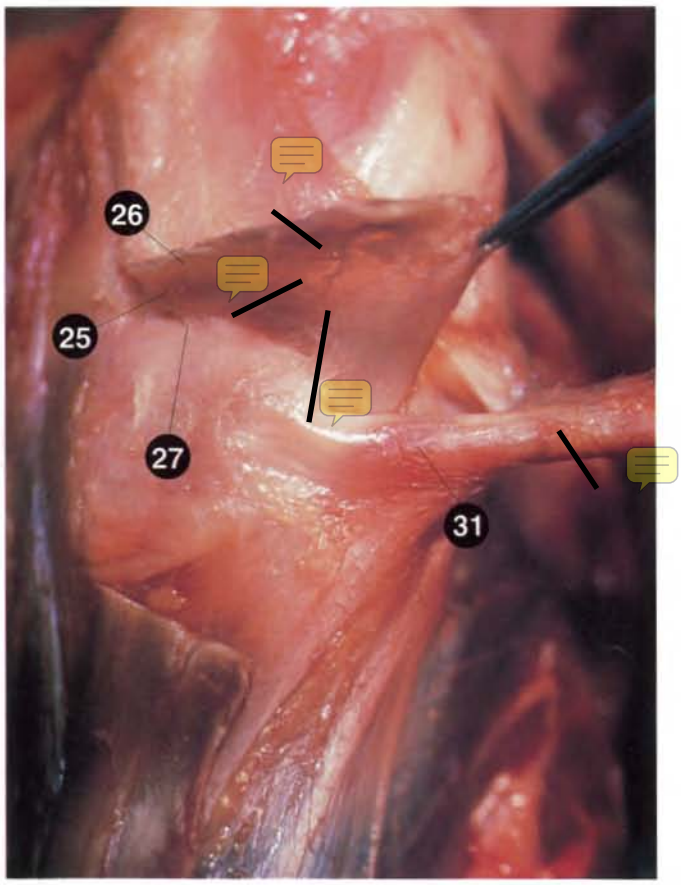

Figure 12

Figure 12 illustrates that by transecting the MCL (16) horizontally, one can see the medial capsular ligament (25) directly. The medial capsular ligament is actually the middle third of the medial capsule, which lies directly beneath the MCL and has fiber orientation similar to that of the MCL. It reaches from the femur to the tibia and is subdivided into the meniscofemoral ligament (26) and the meniscotibial ligament (27) by its attachment to the medial meniscus.

The true function and strength of the medial capsular ligament are controversial. The anterior and posterior thirds of the capsule provide little structural stability, but the thick middle third of the capsule attaches directly to the medial meniscus and provides a secondary restraint to valgus opening and external rotatory forces.

There is a bursal sac between the MCL and the deep capsular ligament, which allows functional motion between these structures. This bursa may become inflamed and cause clinical symptoms that must be differentiated from a medial meniscal tear or bursitis.

While the MCL and the POL are both important in stabilizing the medial side of the knee, we believe the long anterior parallel fibers of the MCL are the prime static stabilizers of the medial side of the knee in resisting valgus stress. The MCL also provides a major restraint to excess tibial rotation (external greater than internal) and provides a small secondary restraint to anterior and posterior tibial translation on the femur.

We believe that while the POL is not the primary static stabilizer of the medial side of the knee, it has an important role in providing both static and dynamic support to the medial and posteromedial aspects of the knee. The POL serves a unique function (mostly through its central arm) acting as a bridge connecting the superficial and deep structures on the medial side, the anterior and posterior structures, and the intra-articular

and extra-articular structures. It probably also serves an important function with regard to meniscal stability, mobility, and protection.

The semimembranosus tendon (Figs. 12–18) has five attachments, or limbs, to structures about the posteromedial aspect of the knee: the first limb (29), the second limb (30), the third (medial) limb (31), the fourth (direct) limb (32), and the fifth limb (33). This complex array of attachments makes it the primary dynamic stabilizer of the posteromedial aspect of the knee.

The first limb (29) of the semimembranosus tendon (Fig. 14) extends laterally and obliquely across the posterior capsule to form a thickened structure called the oblique popliteal ligament (34), which must be differentiated from the POL (21).

The second limb (30) (Figs. 15–17) attaches to the posterior capsule (35), the POL (21), and the posterior portion of the medial meniscus (36). This segment dynamically aids in displacing the medial meniscus posteriorly during flexion and helps tension the POL during knee motion. It also reinforces the posterior capsule. Figure 15 shows the expansions to the posterior capsule. Figure 16 shows expansions to the medial meniscus, POL, and posterior capsule; these expansions exert tension on their insertions during extension of the knee. Figure 17 shows how the same expansions exert tension on these structures in flexion.

The third limb (31) (Figs. 12, 13) passes medially along the proximal portion of the tibia and disappears under the superficial portion of the MCL to insert on the medioproximal aspect of the tibia.

The fourth limb (32) (Figs. 16, 17) attaches directly onto the posterior medial tibial condyle (medial tuberosity) 1 to 2 cm below the joint line.

The fifth limb (33) (Fig. 18) passes distally and blends into the popliteal fascia and the posterior and medial periosteum of the tibia.

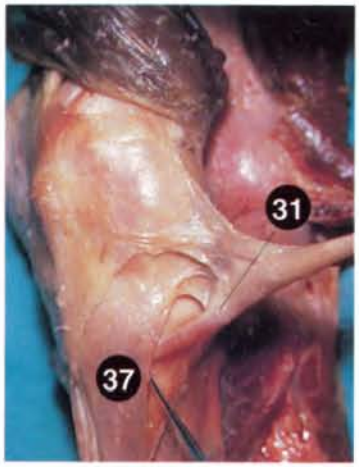

Figure 13

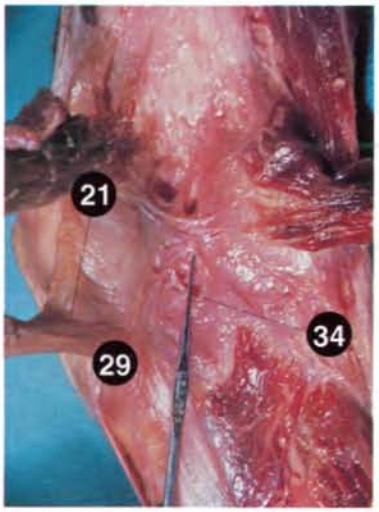

Figure 14

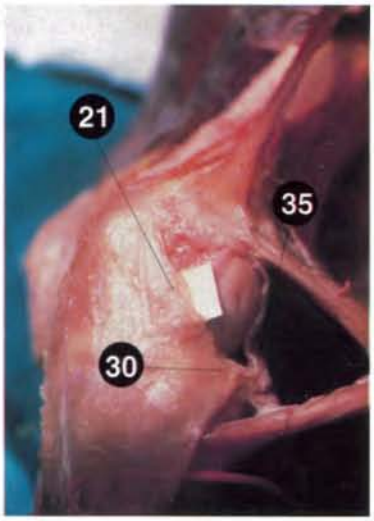

Figure 15

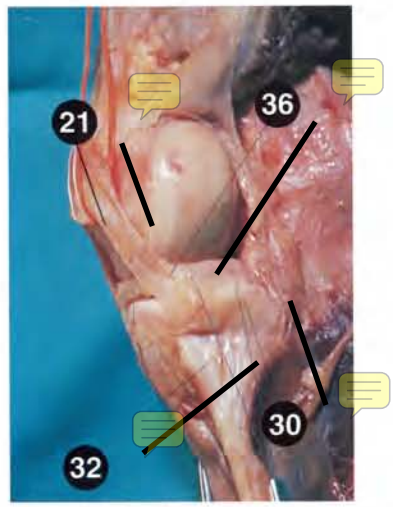

Figure 16

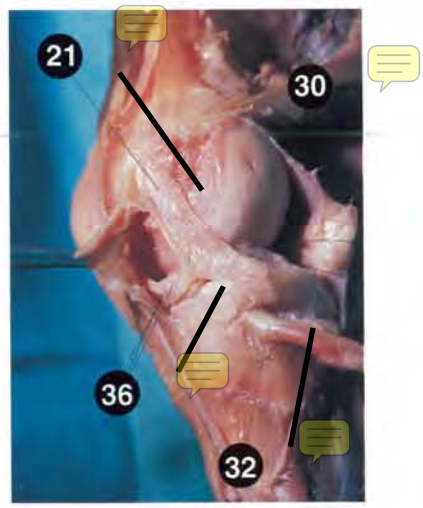

Figure 17

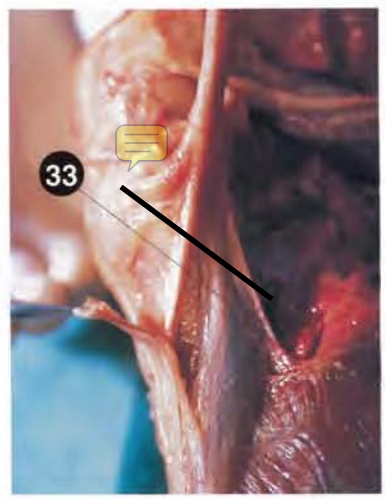

Figure 18

The semimembranosus musculotendinous unit is part of the ischiocrural muscle units originating from the ischial tuberosity. It is considered the prime stabilizer of the posteromedial corner of the joint. Slocum et al recommend its use during acute repairs and late reconstructive procedures on the medial side of the knee. Hughston recently reported the long-term efficacy of using this tendon to enhance and augment repairs of the posteromedial corner of the knee.

The semimembranosus–tibial collateral ligament bursa (37)(Fig. 13) is an inverted U-shaped bursal sac that lies between the superficial MCL and the main insertion (third limb) of the semimembranosus tendon. It then curls over the top of the tendon and tracks back down underneath the tendon between tendon and bone. The sac has an elliptical superficial portion and a deep triangular portion.

Bursitis in this region must be differentiated from the bursitis in the more distal pes anserinus bursa or in the more proximal posterior semimembranosus–gastrocnemius bursa. Ray et al have reported semimembranosus tendinitis as an overlooked cause of medial knee pain and have described an appropriate workup, as well as conservative and surgical treatment for this problem. A medial meniscal tear must be included in the differential diagnosis.

When performing a total knee arthroplasty, subperiosteal release of the semimembranosus attachments improves visualization of the posteromedial corner. This allows for increased anterior tibial excursion and external rotation during tibial positioning, which relieves tension from the patellar tendon at its insertion into the tibial tubercle. This technique is extremely useful when trying to gain exposure of the tibial plateau in the severely deformed varus knee and in total knee revisions.

Suggested Reading

Baker CL Jr, Shalvoy R: Treatment of acute and chronic injuries to the medial structures of the knee. *Operative Techniques Sports Med* 1996;4:166-173.

Burger RS, Greenleaf JE, James S: *Atlas of Knee Anatomy.* St Louis: Mosby (in press).

Burger RS, Larson RL: Acute ligamentous injury, in Larson R, Grana W (eds): *The Knee: Form, Function, Pathology, and Treatment.* Philadelphia: Saunders, 1993, pp 520-533.

Burger RS, Larson R: Chronic anterior, anterolateral and anteromedial instability, in Larson R, Grana W (eds): *The Knee: Form, Function, Pathology, and Treatment.* Philadelphia: Saunders, 1993, pp 609-621.

Hughston JC: The importance of the posterior oblique ligament in repairs of acute tears of the medial ligaments in knees with and without an associated rupture of the anterior cruciate ligament: Results of long-term follow-up. *J Bone Joint Surg Am* 1994;76:1328-1344.

Hughston J, Eilers A: The role of the posterior oblique ligament in repairs of acute medial liagment tears of the knee. *J Bone Joint Surg Am* 1973;55:923-940.

James SL: Biomechanics of knee ligament reconstruction. *Clin Orthop* 1980;146:90-101.

James SL: Surgical anatomy of the knee. *Fortschr Med* 1978;96:141-146, 166.

James SL: Surgical anatomy of the knee, in Schulitz KP, Krahl H, Stein WH (eds): *Late Reconstructions of Injured Ligaments of the Knee.* Berlin: Springer, 1978, pp 3-18.

Larson RL, Burger RS: Medial instability of the knee, in Chapman MW (ed): *Operative Orthopaedics,* 2nd ed. Philadelphia: Lippincott, 1993, pt 9, pp 2115-2130.

Ray JM, Clancy WG Jr, Lemon RA: Semimembranosus tendinitis: An overlooked cause of medial knee pain. *Am J Sports Med* 1988;6:347-351.

Slocum D, Larson R: Pes anserinus transplant: A simple surgical procedure for control of rotatory instability of the knee. *J Bone Joint Surg Am* 1968;50:226-242.

Slocum D, Larson R, James S: Late reconstruction of ligamentous injuries to the medial compartment of the knee. *Clin Orthop* 1974;100:23-66.

Slocum D, LarsonR, James S: Pes anserinus transplant: Impressions after a decade of experience. *Am J Sports Med* 1974;2:123-136.

Strobel M, Stedtfeld HW: *Diagnostic Evaluation of the Knee.* Berlin: Springer, 1990, pp 17-27.

Dr. Burger is in private practice in Sacramento, Calif. Dr. Greenleaf is in private practice in Tualatin, Oregon. Dr. James is Associate Clinical Professor of Surgery, School of Medicine, Oregon Health Sciences University, Portland, and is in private practice in Eugene, Ore.

Corresponding contributor: Dr. Burger, Department of Orthopaedic Surgery, 1600 Eureka Road, Roseville, CA 95661.