Intern Arthroscopy Course 2015
Shoulder Arthroscopy Cases

Mary Lloyd Ireland, M.D.
University of Kentucky
Dept. of Orthopaedic
Surgery & Sports Medicine
Lexington, KY



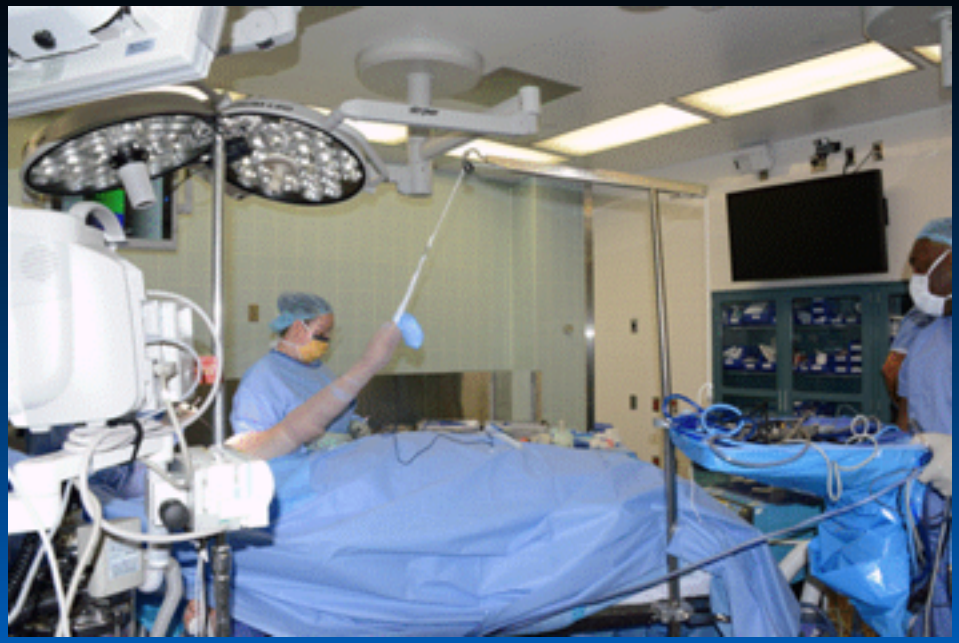



Broken screw s/p Bristow procedure



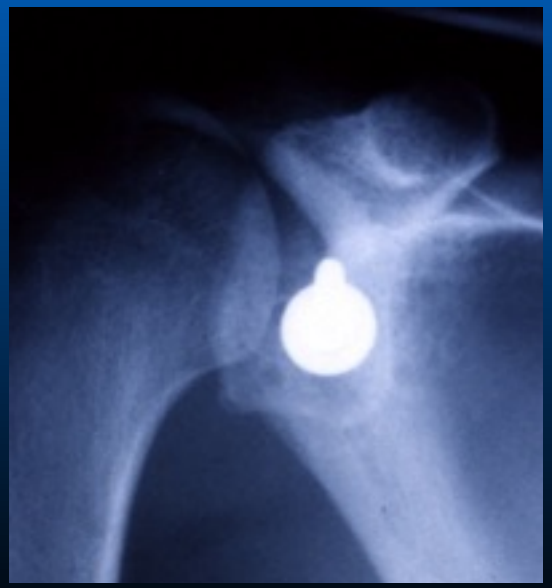



Beware prominent hardware in the shoulder.
It breaks, erodes cartilage, etc. . . .



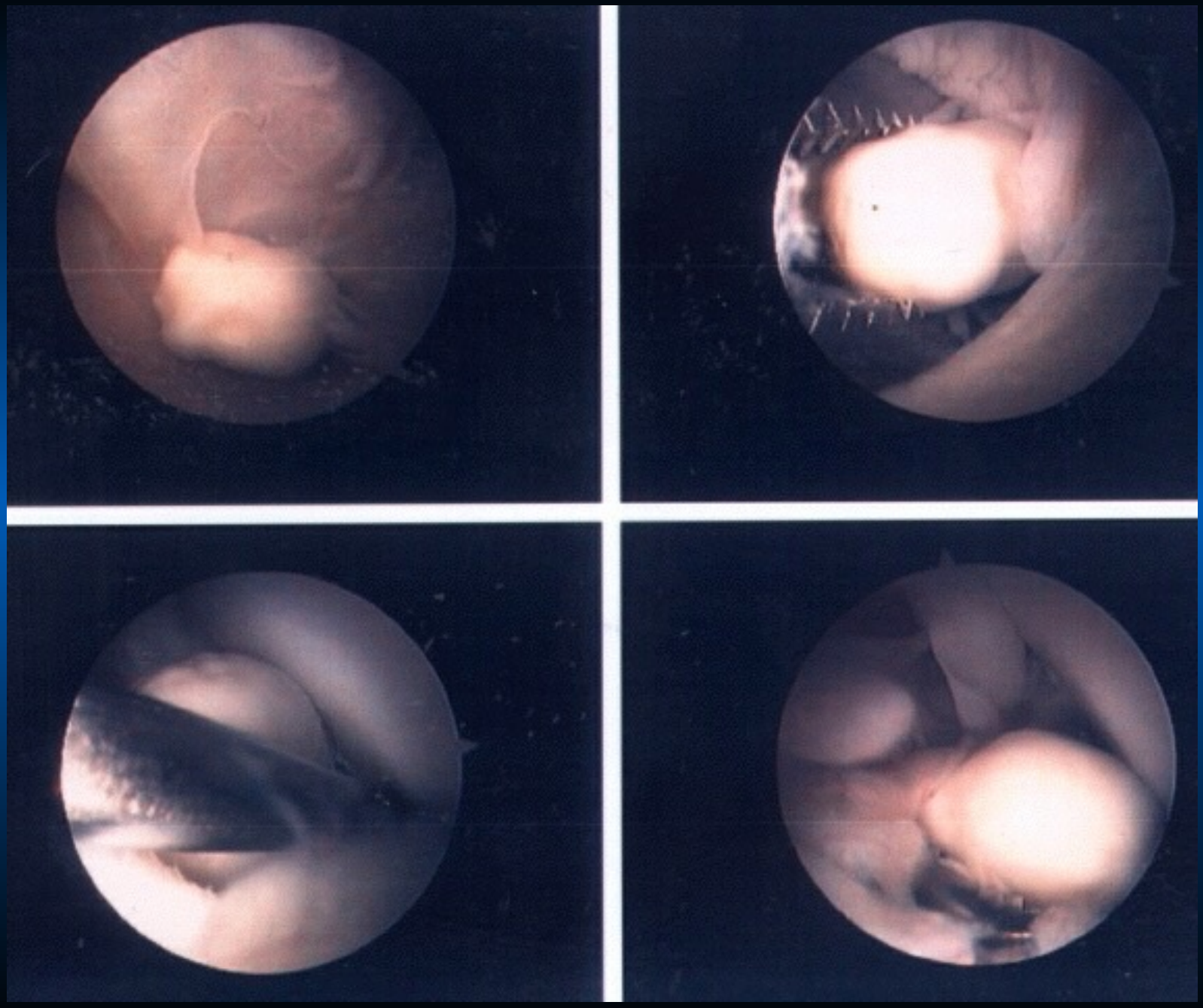

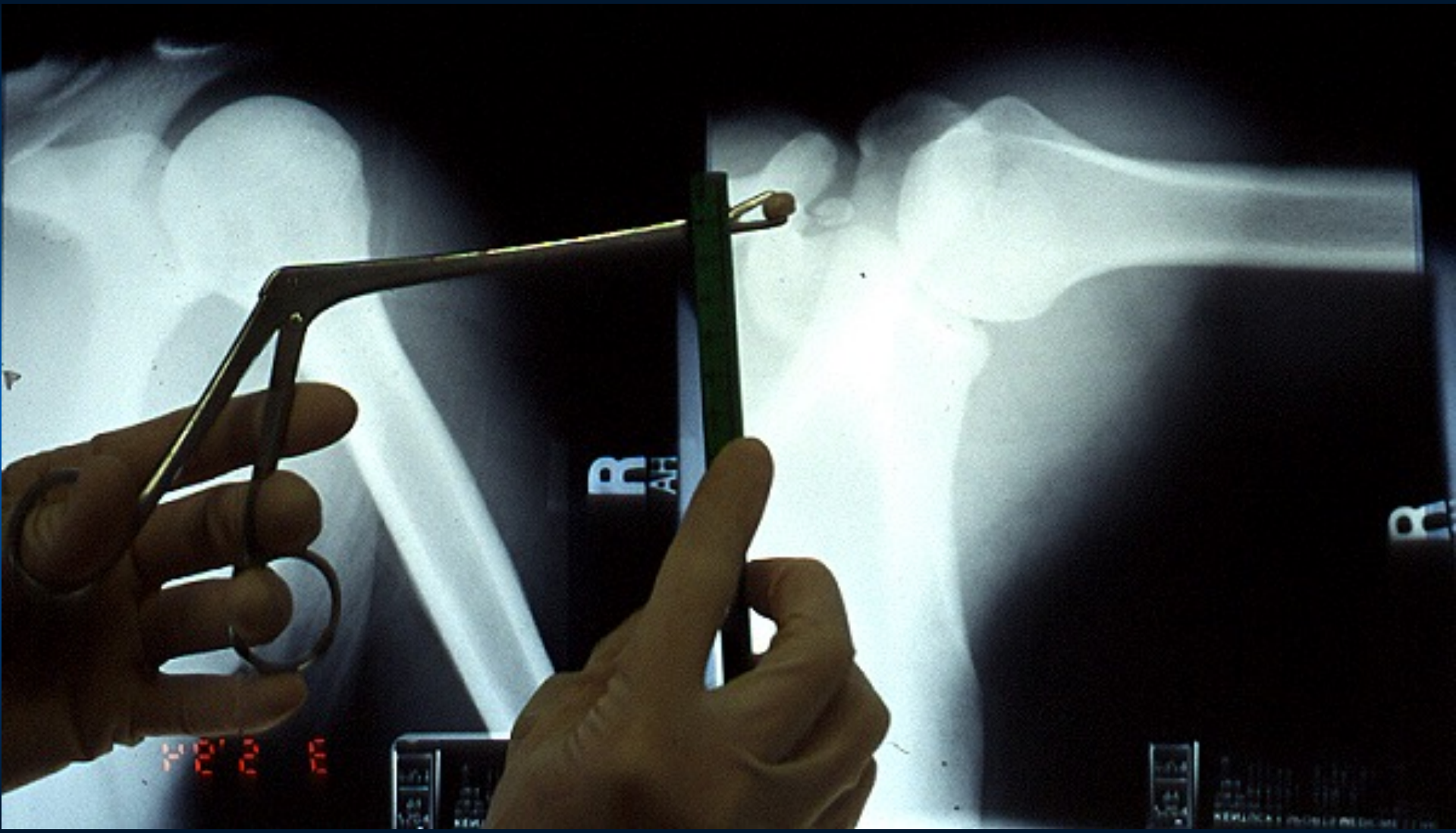

Complications

- How I have managed my own complications
- If using new equipment,
  know how to get out of trouble
- Frustrating to break arthroscopic instruments
- Be patient!
- Be honest!

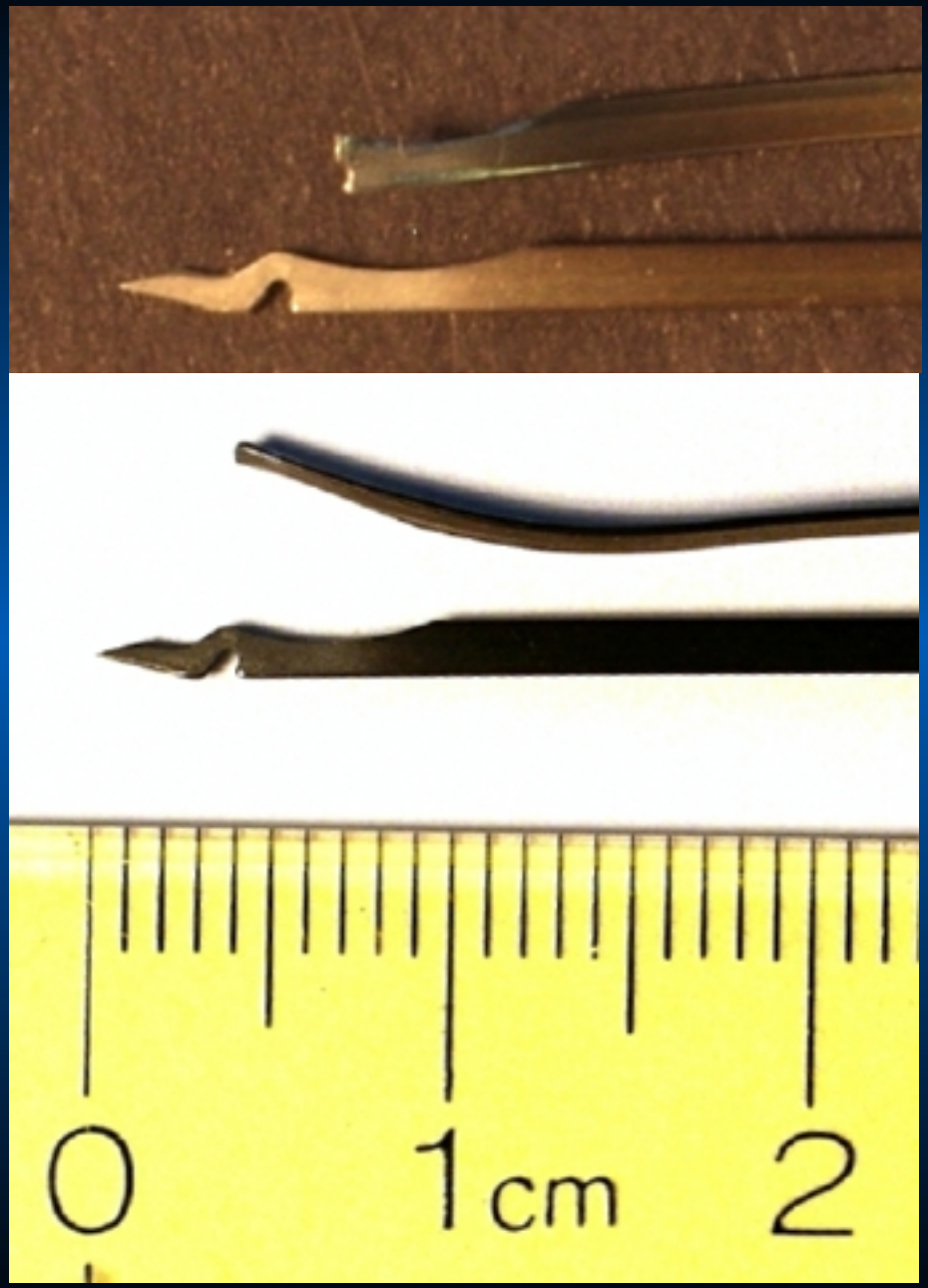
0
1 cm
2

Sutures placed in rotator cuff, arthroscopically-aided with Expressew; tip of needle broke off

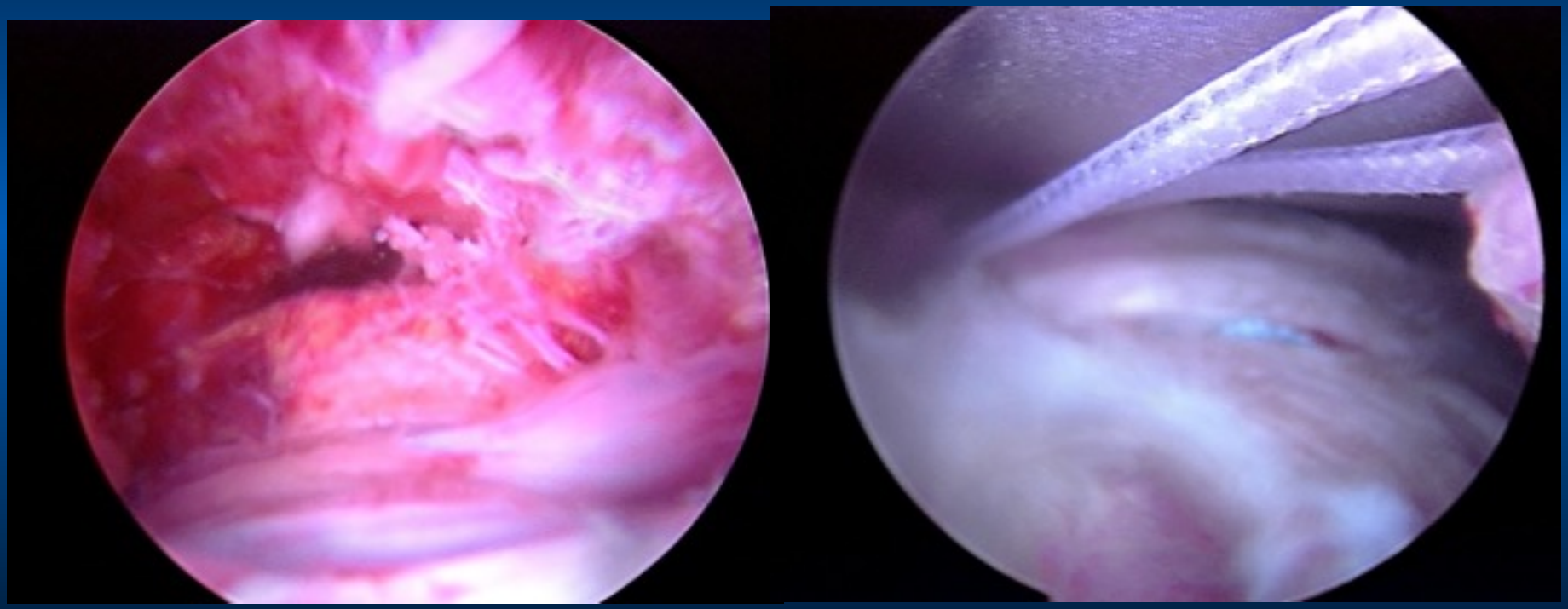

Search for needle tip not successful
Embedded in thick rotator cuff

C-Arm View

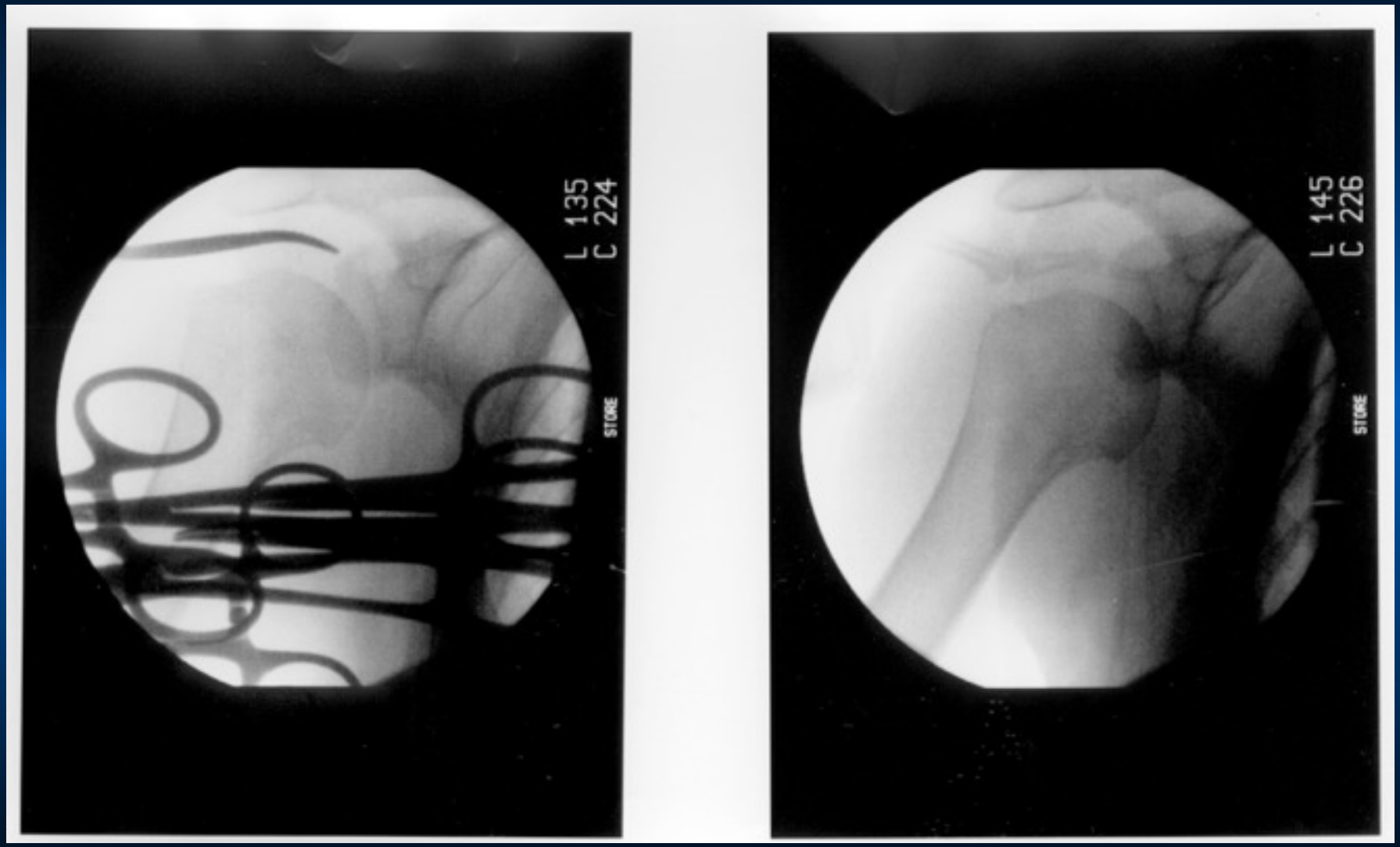

Mini-open rotator cuff repair performed



C-Arm used to locate needle tip
Informed family of breakage of instrument
Post-op xrays taken in office

2 week Follow Up

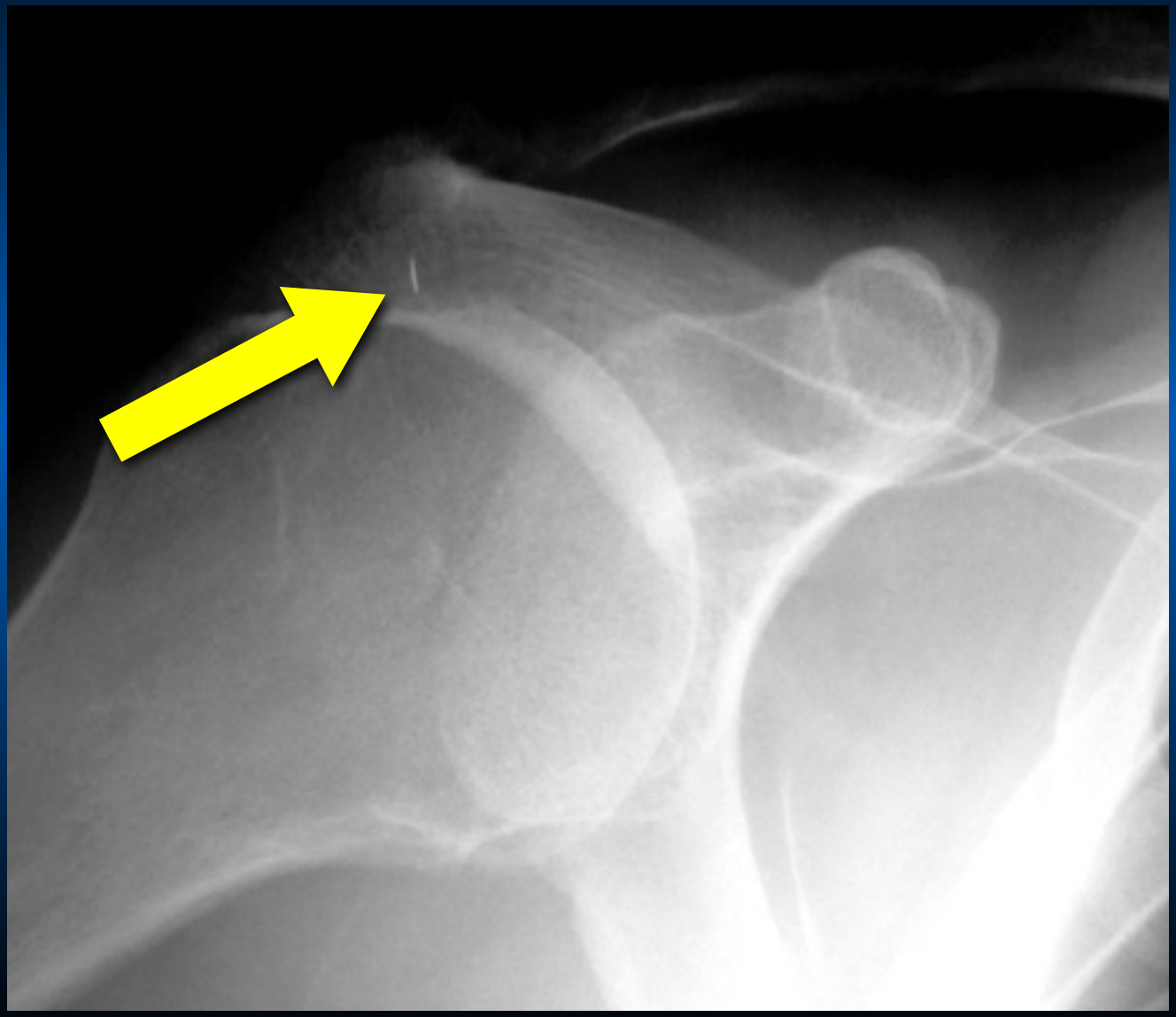



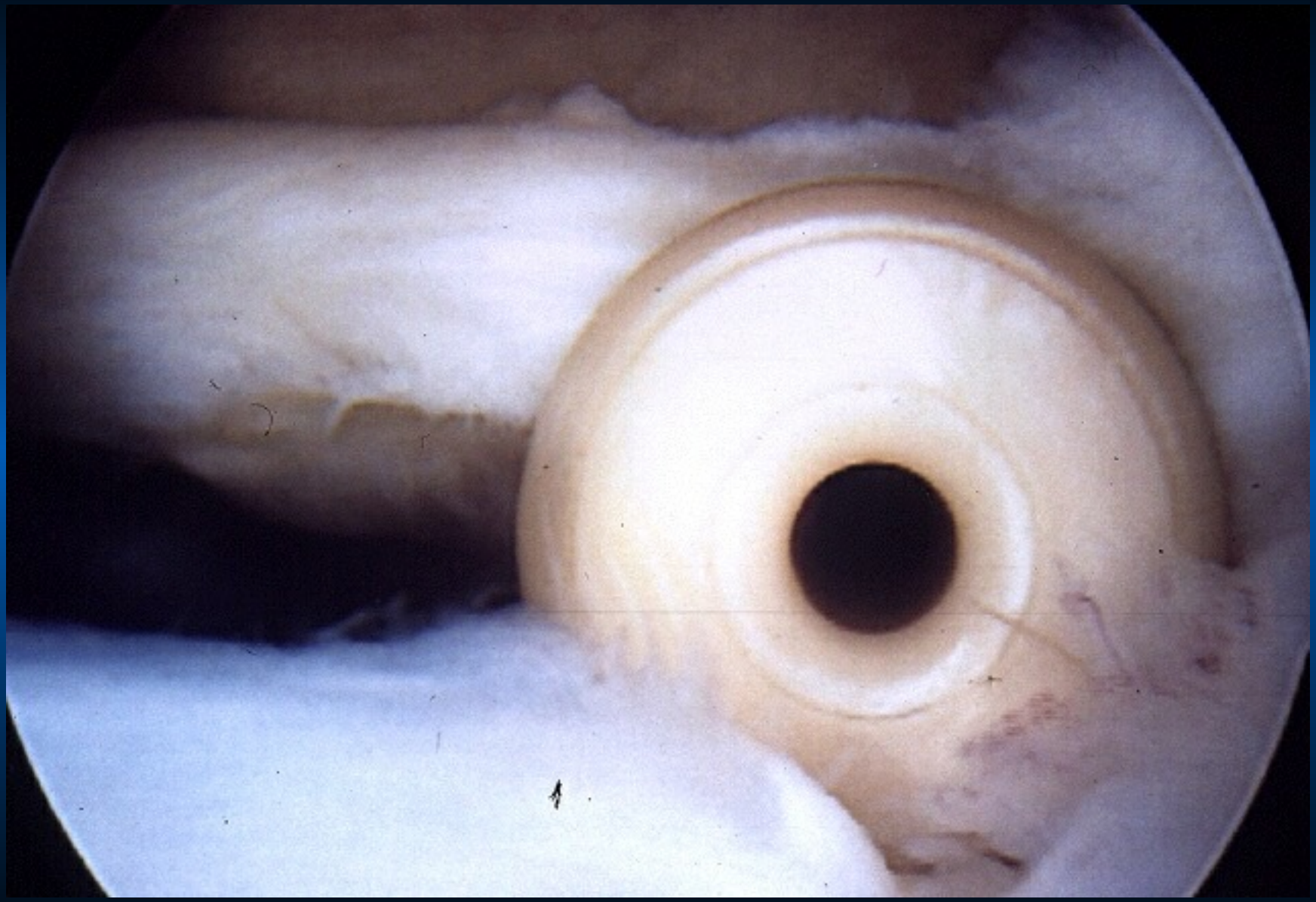

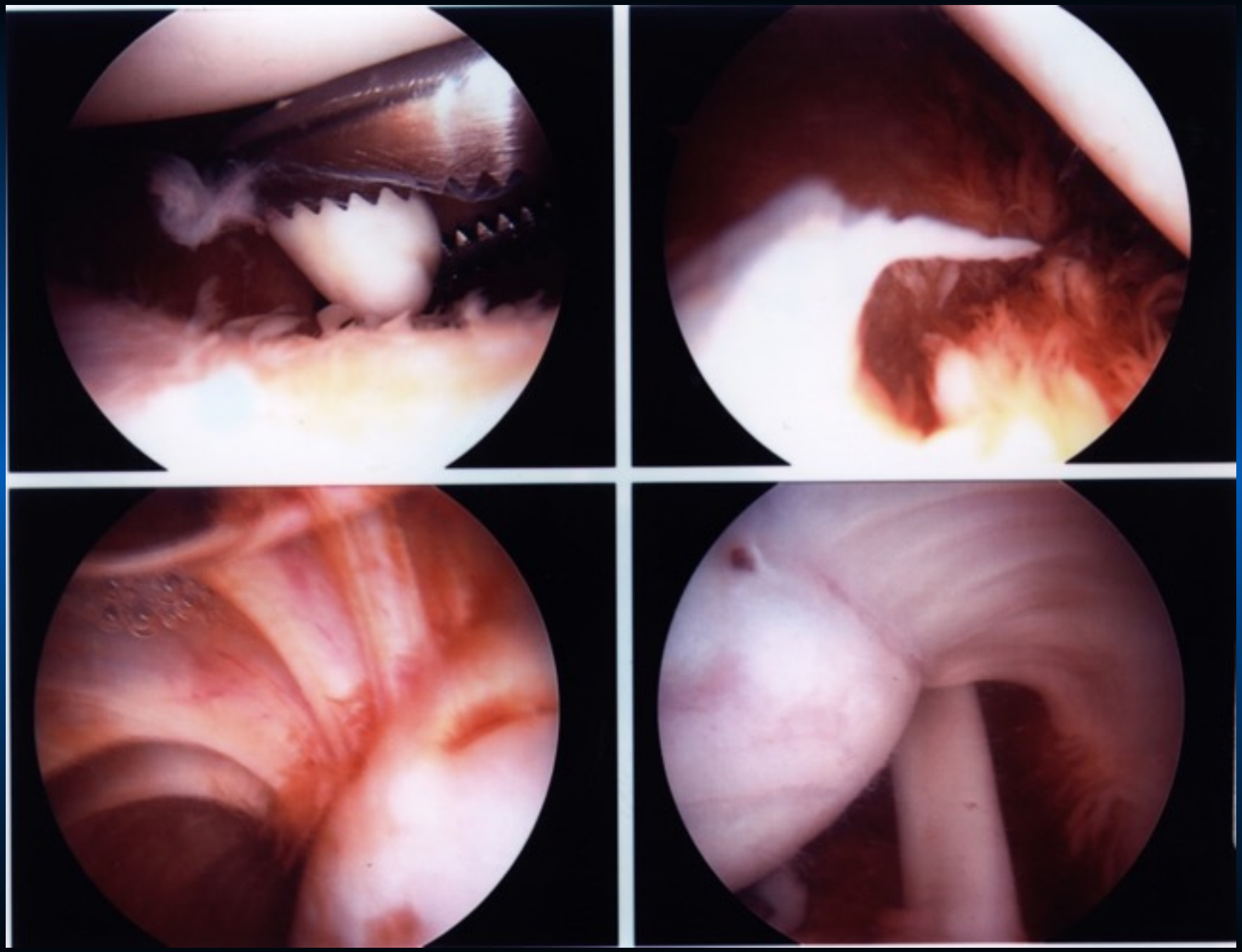

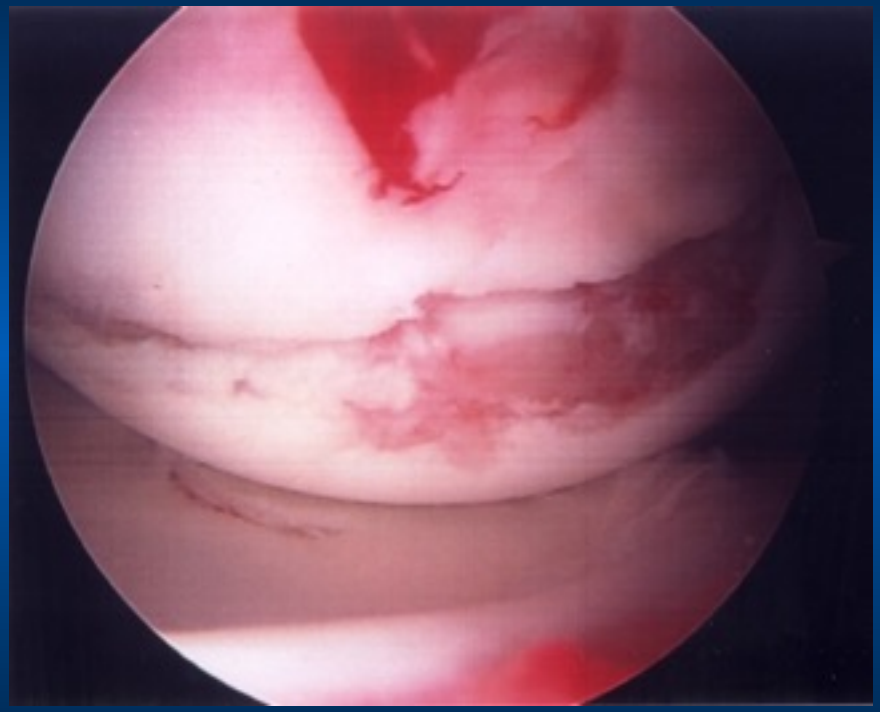

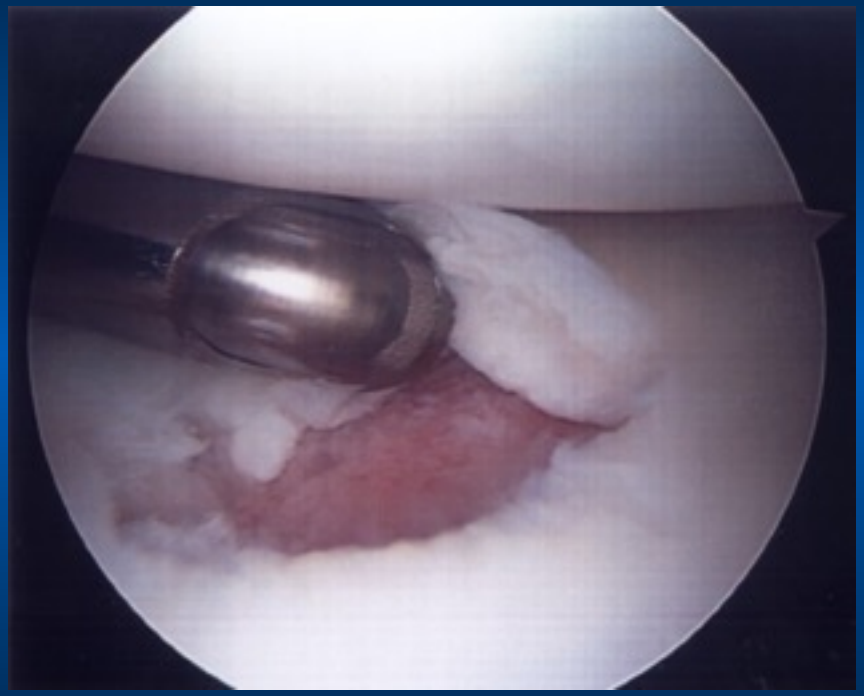

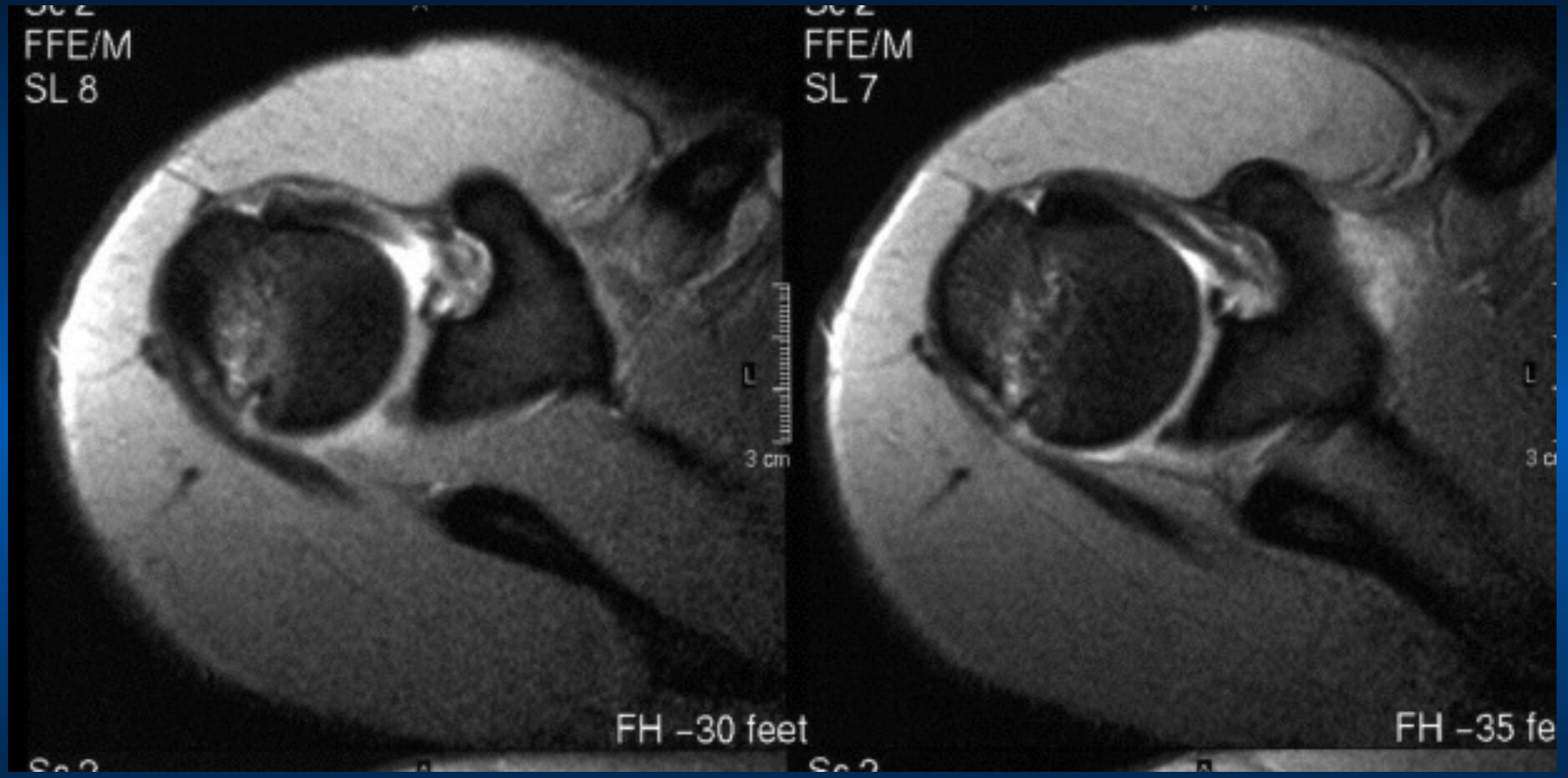
FFE/M
SL 8
3 cm
FH -30 feet
FFE/M
SL 7
FH -35 fe





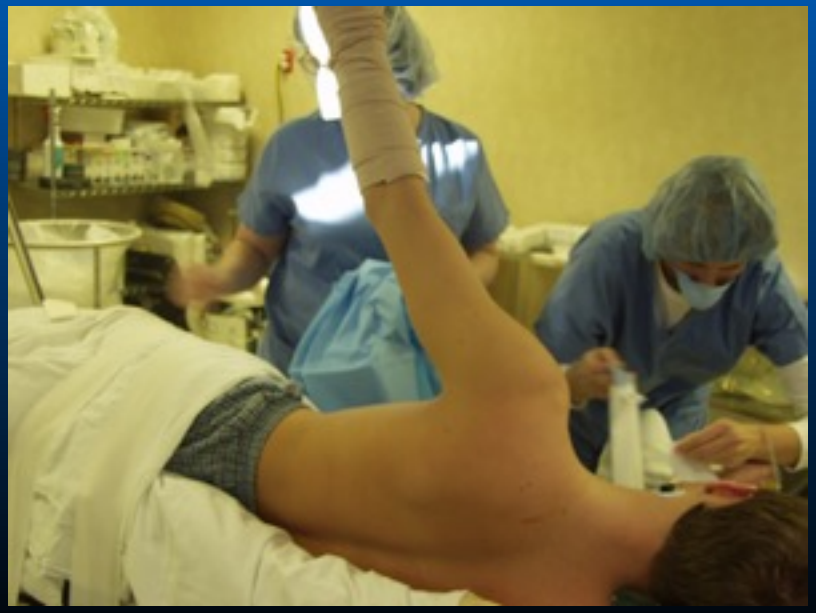



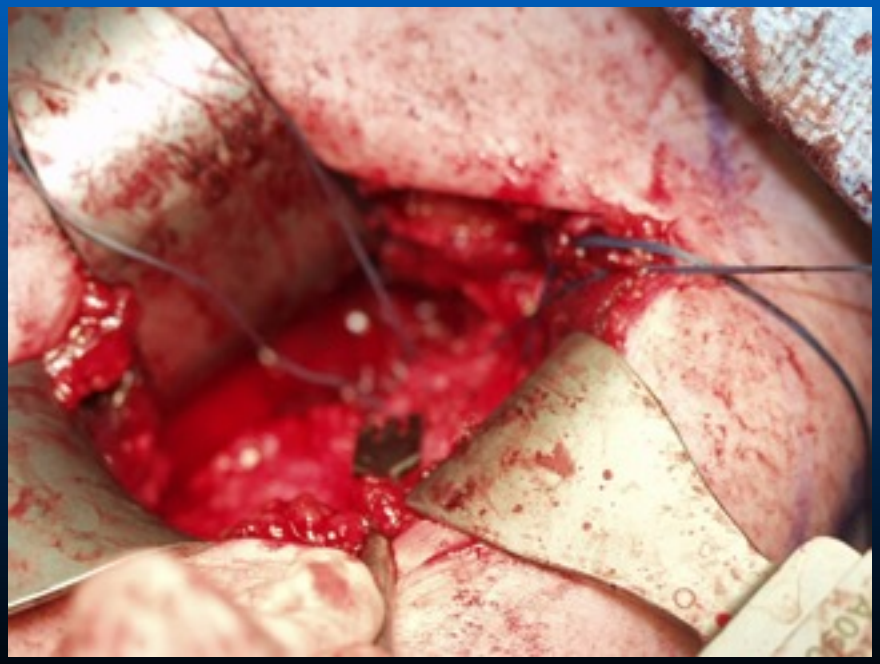
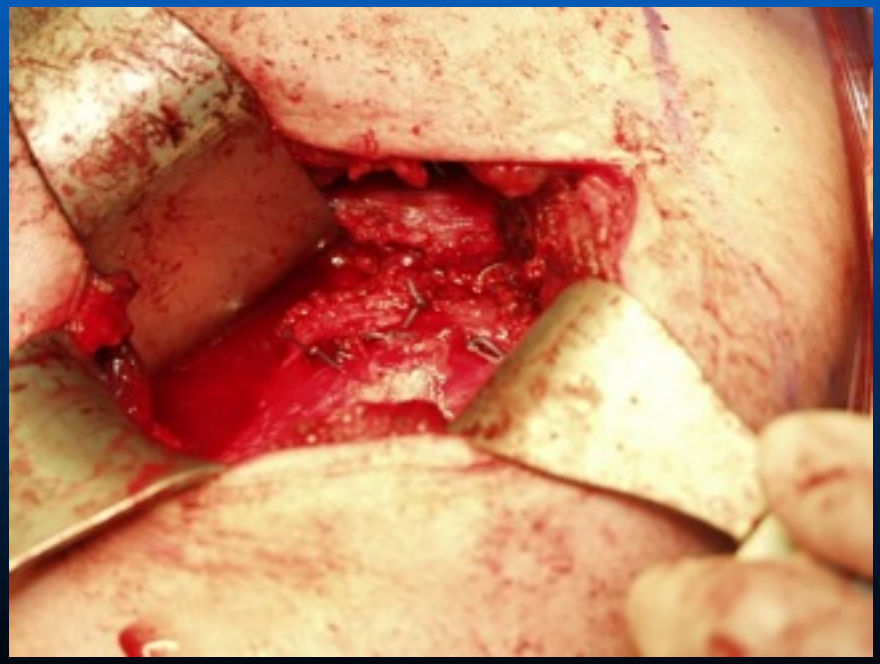

Bankart lesion and capsular insufficiency



Preparation of the glenoid, mobilization of capsuloligamentous labral tissue from scapular neck

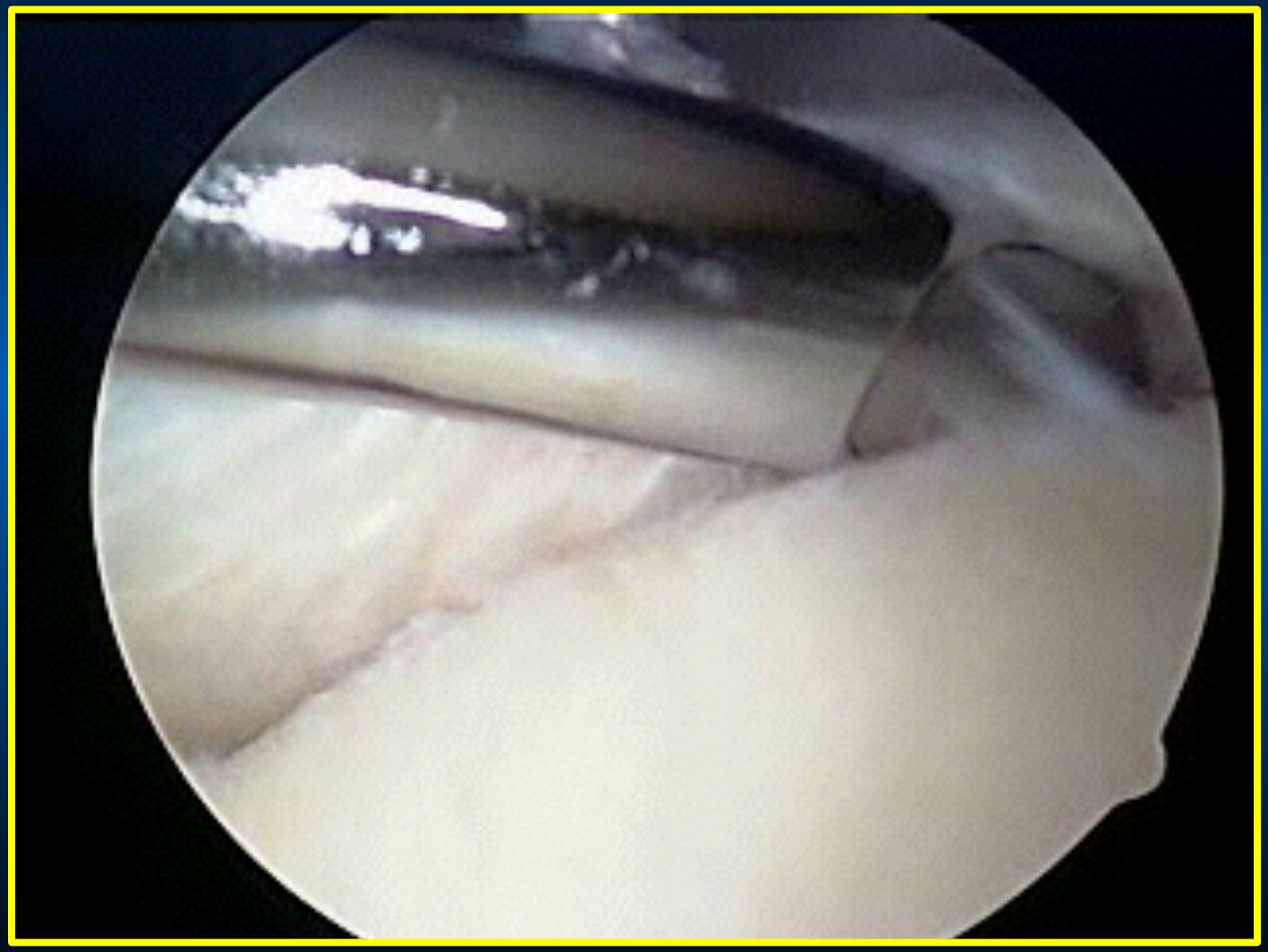

Suture management, 2 anchors with 4 sutures and capsulorraphy sutures inferior and rotator interval



Completed stabilization rotator interval closure, re-establishment of anterior capsuloligamentous labral structures

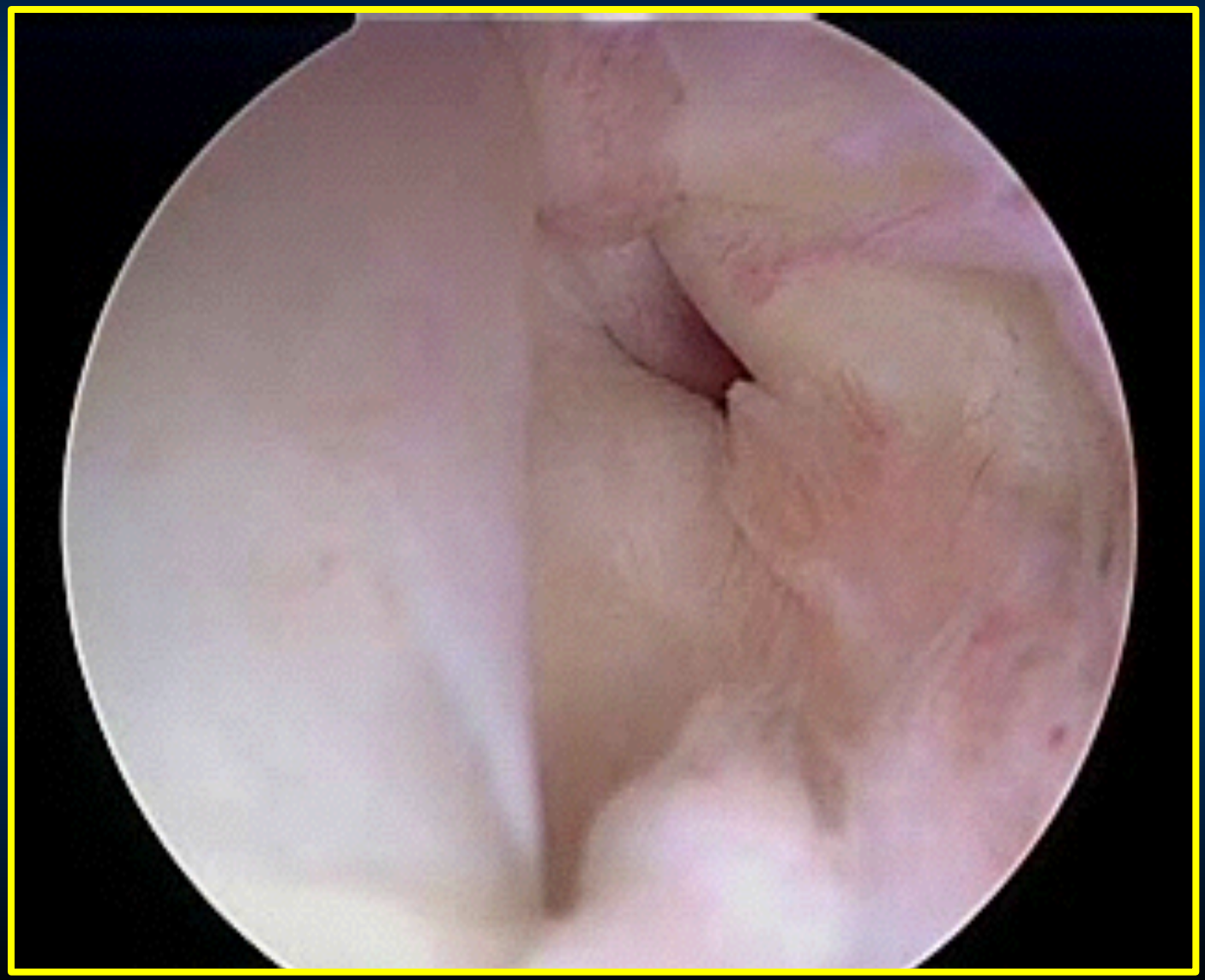












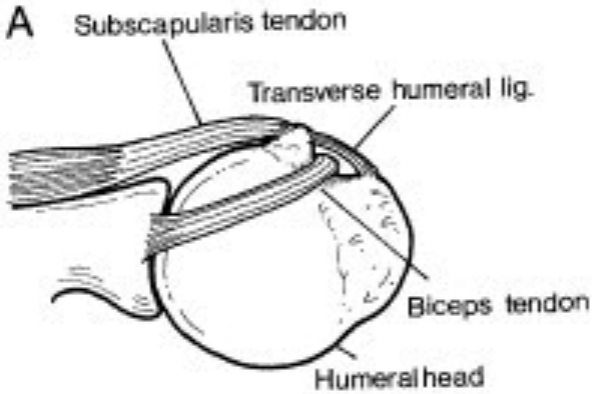

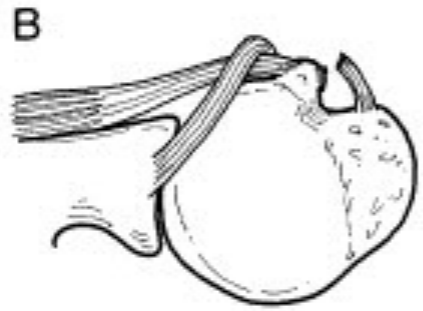



FIG 4. Superior view of right shoulder. (**A**) Normal relation of biceps tendon to bicipital groove. (**B**) Rupture of transverse humeral and coracohumeral ligaments, but no disruption of subscapularis tendon. (**C**) Tear of subscapularis tendon and coracohumeral and transverse humeral ligaments (as occasionally occurs when the humerus dislocates anteriorly. (Modified from Hitchcock HH, Bechtol CO. Observations on the role of the tendon of the long head of the biceps brachii in its causation. *J Bone Joint Surg* 1948;30A:263–273, with permission).

Bicepital Groove

Biceps Tendon

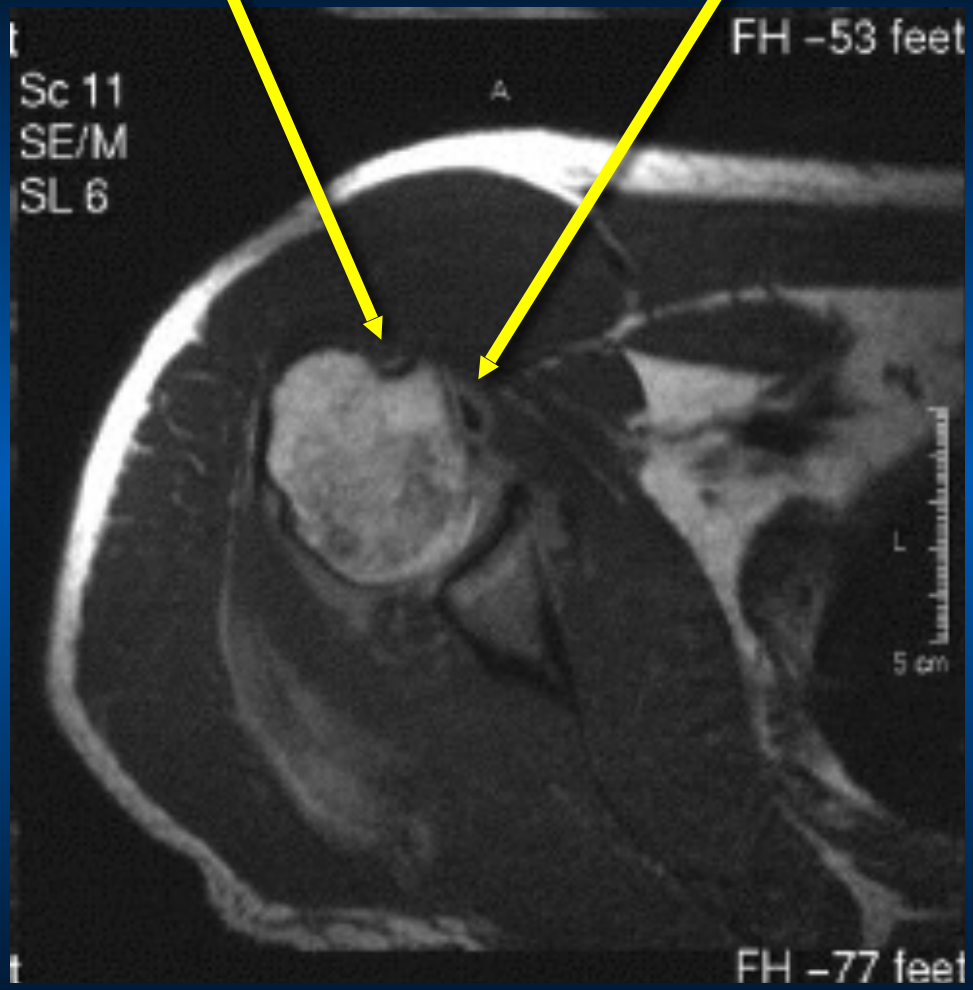

Operation

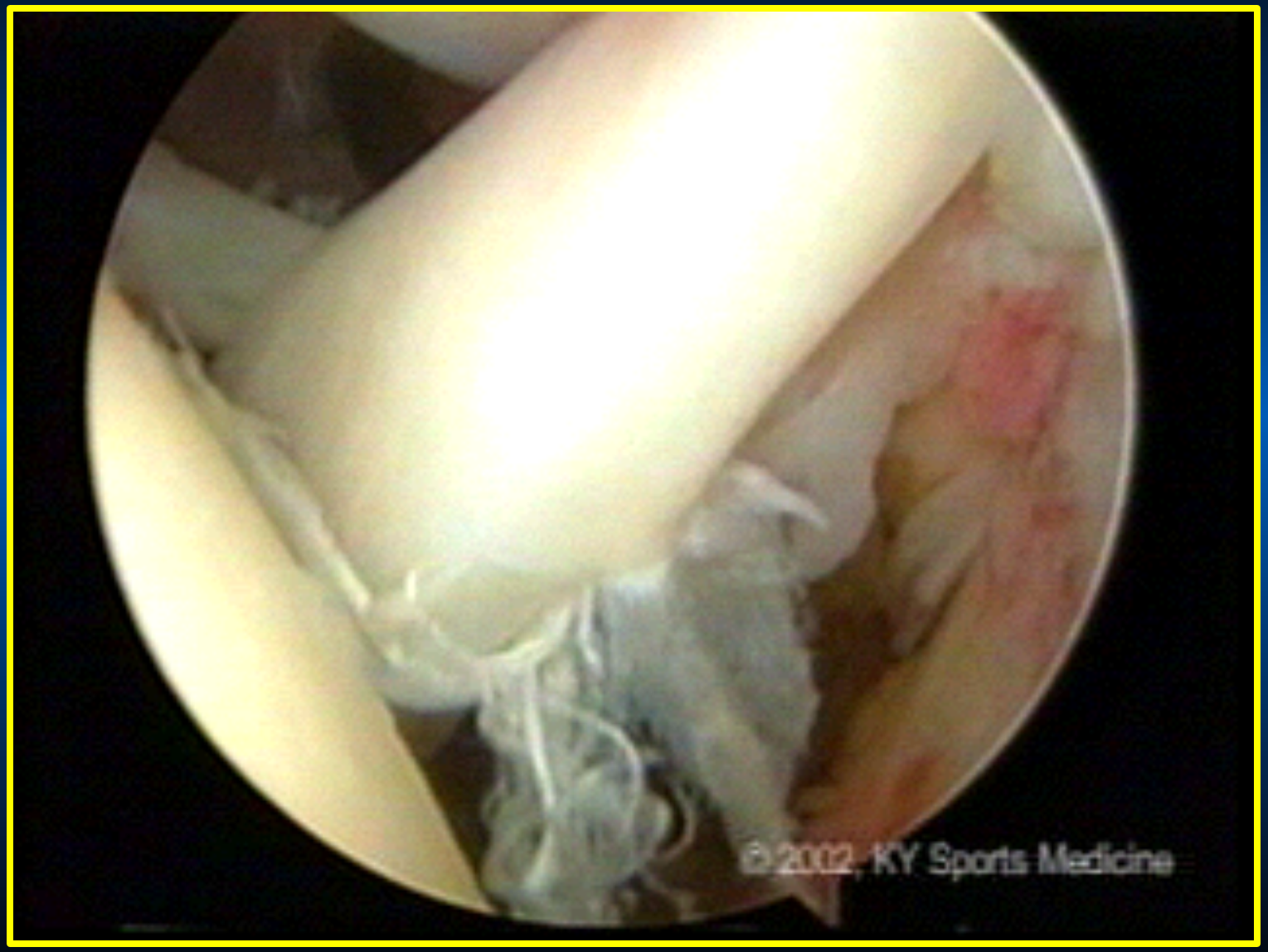

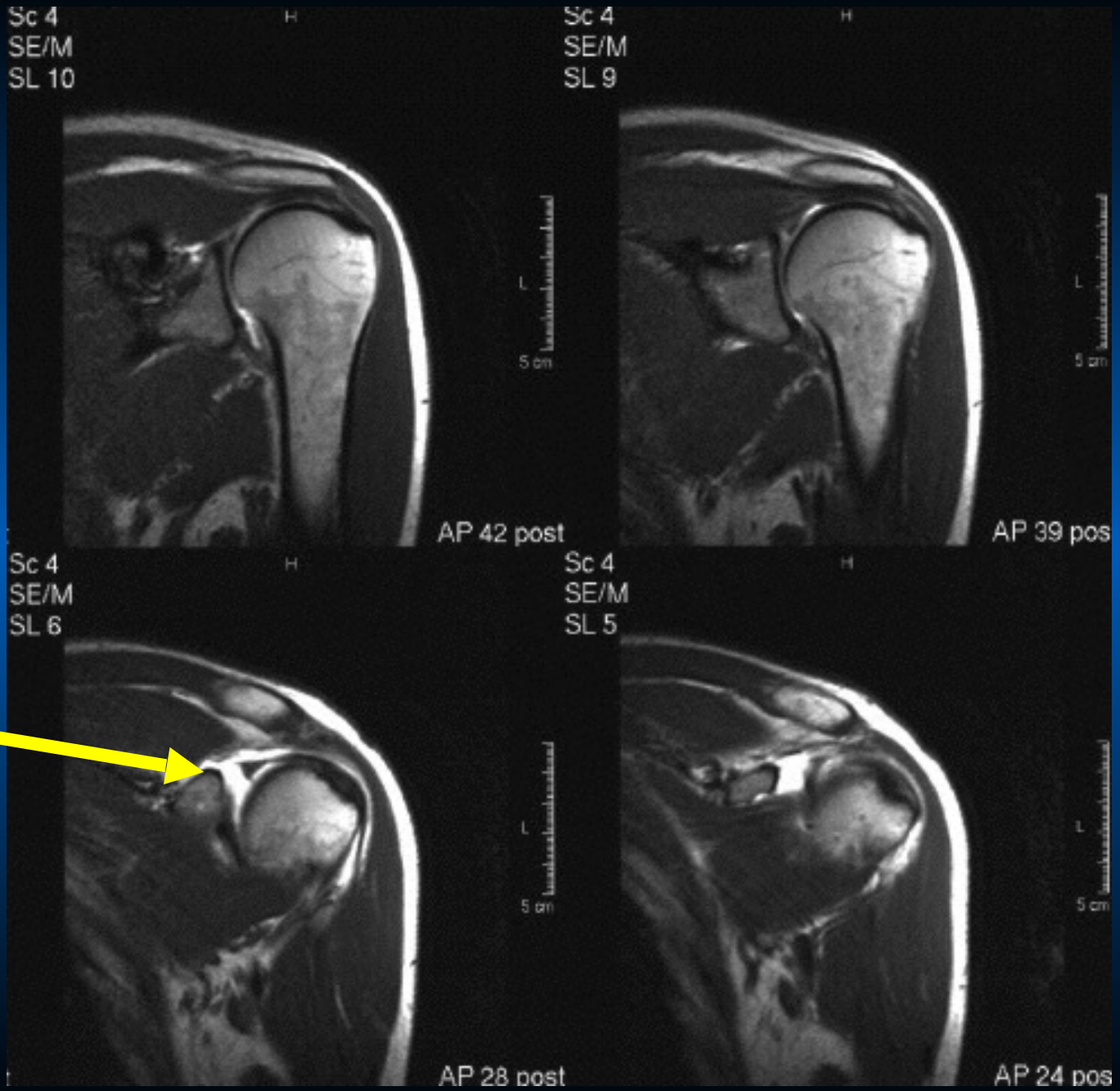
Sc 4
SE/M
SL 10
AP 42 post
Sc 4
SE/M
SL 9
AP 39 pos
Sc 4
SE/M
SL 6
AP 28 post
Sc 4
SE/M
SL 5
AP 24 pos

Arm position hyper-abduction IR



Physical Exam

- Weakness on RC testing 3/5
- Pain on exam
- Significant laxity
  - A>P








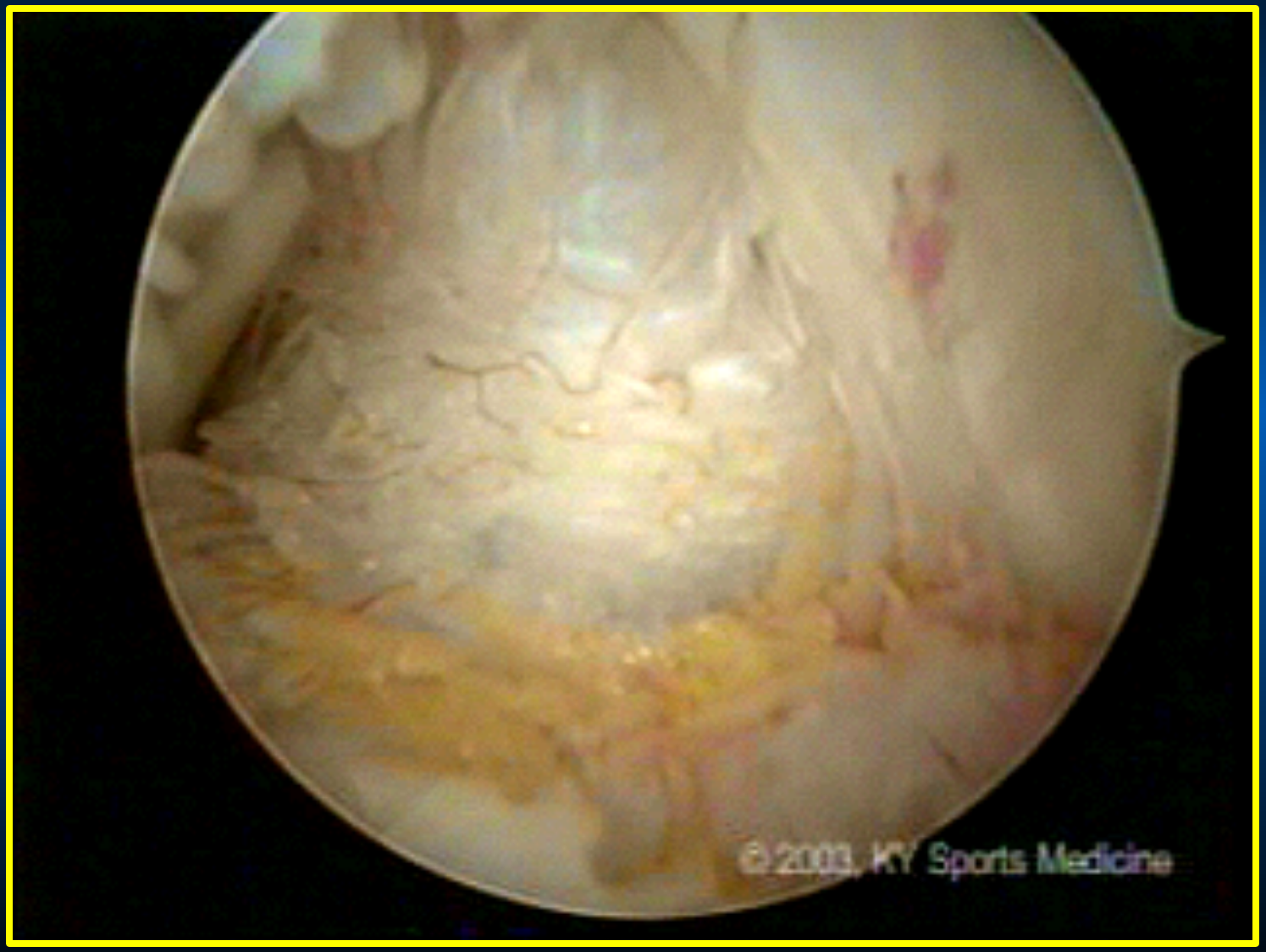
© 2003, KY Sports Medicine

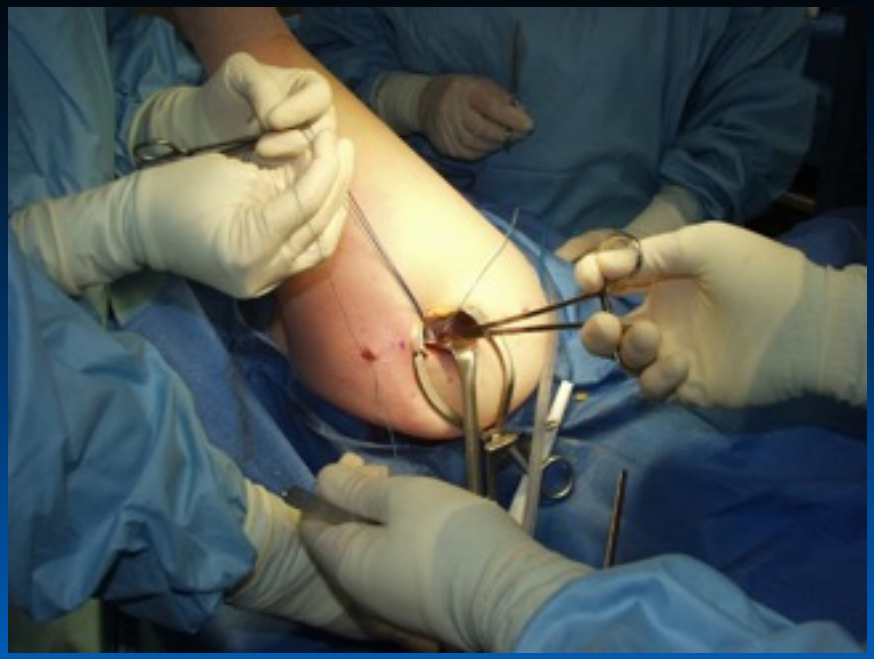




Thermal Capsular Modification

- I don’t use
- Is not successful in MDI patient
- With improved suture-passing devices and anchors, tie instead of fry
- Improved results in elite professional baseball athletes with suturing has been reported (J. Andrews et. al.)

brownJCthermal.mpg



Capsular Necrosis

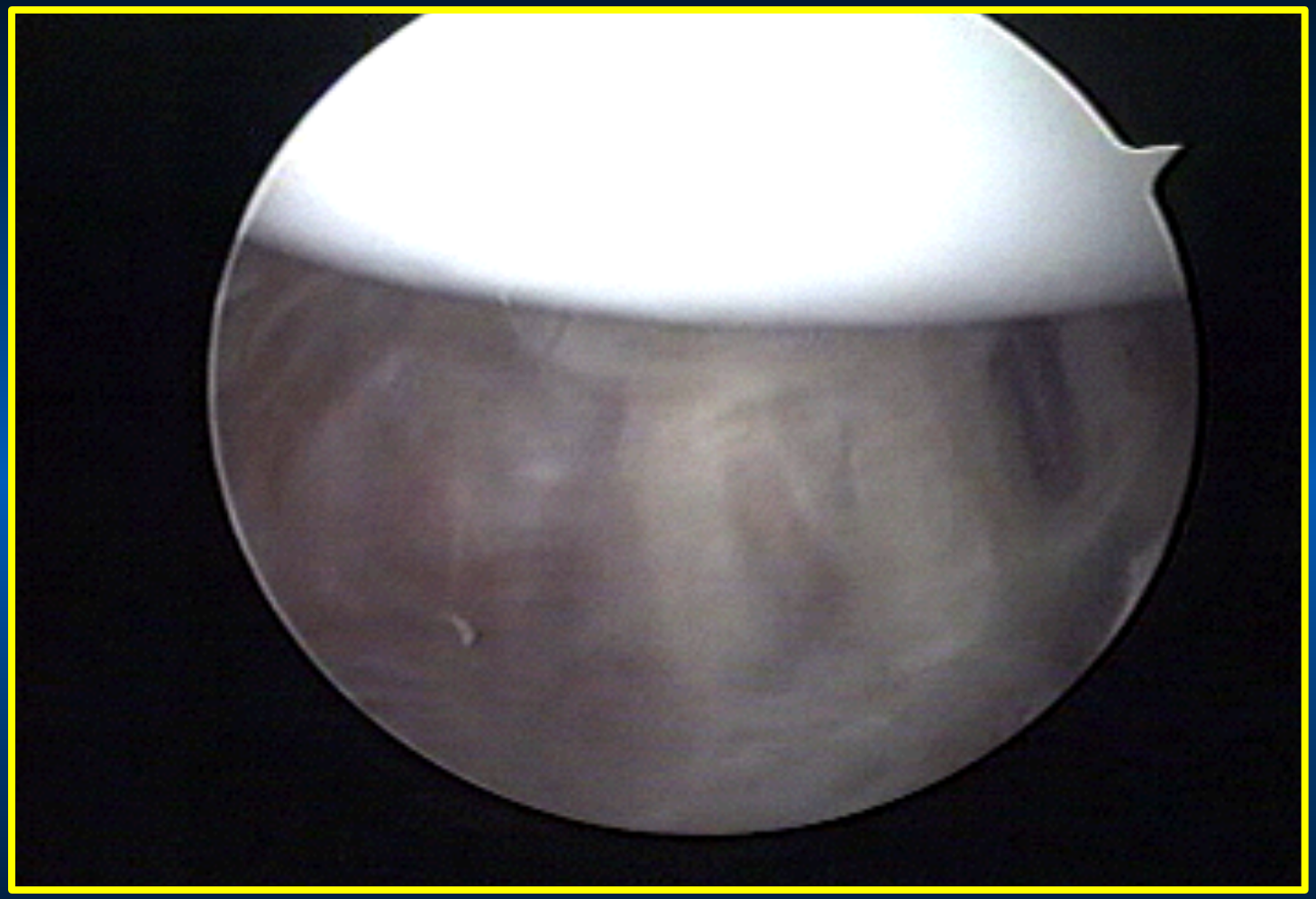

Courtesy of Tony Romeo, M.D.



Thermal Shrinkage of Bacon



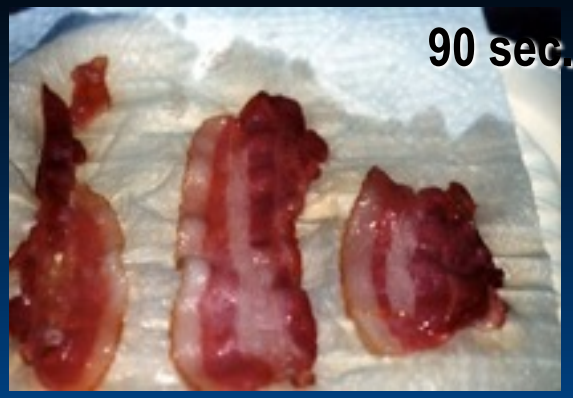



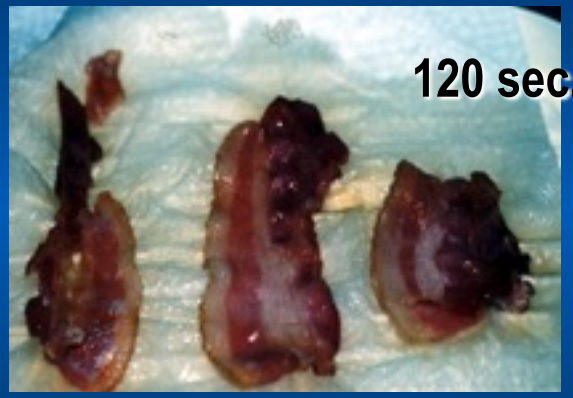

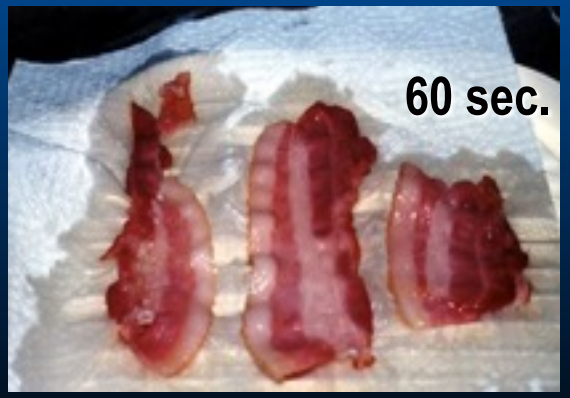

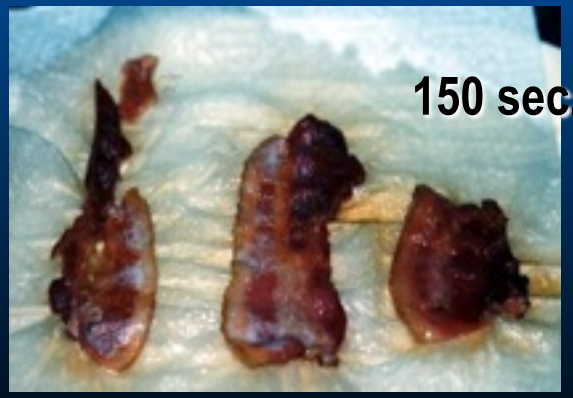

Thermal on cartilage kills cells

- Killing is BAD



- You may get away with it, but…

“Take nothing on its looks. Take everything on evidence. There is no better rule.”

- Charles Dickens

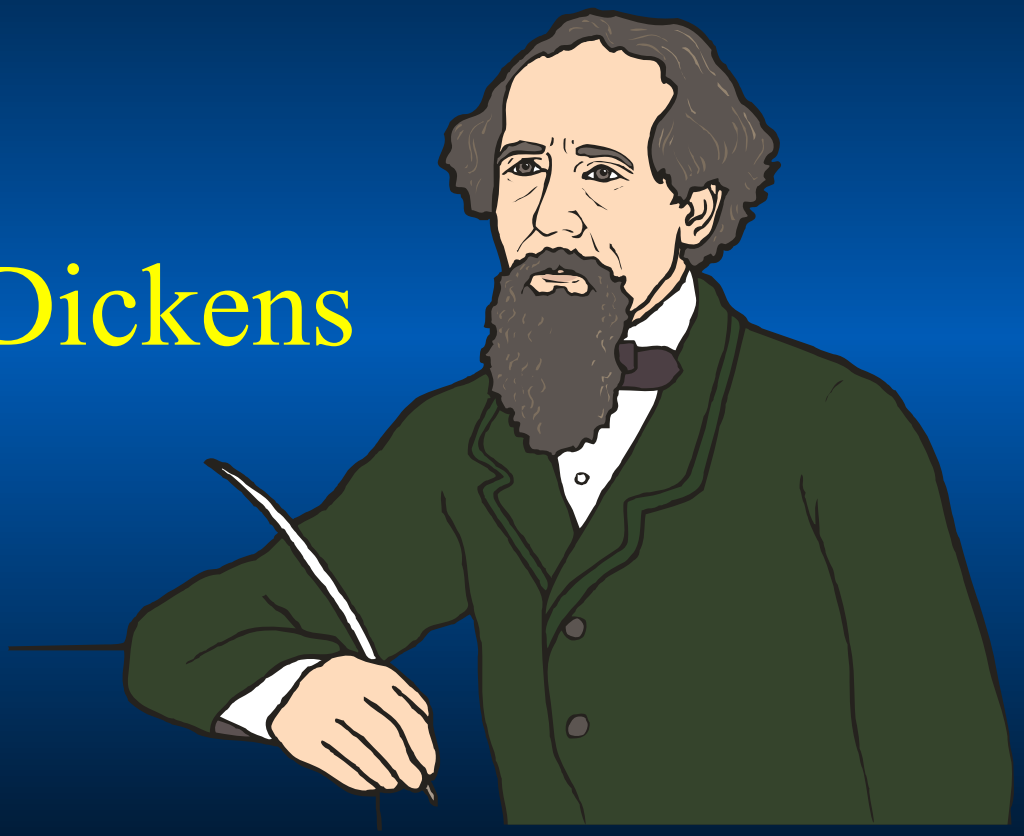

Case 1
Chronic SLAP & Anterior Instability

- 24 YO Right hand dominant high school pitcher, boxer
- History of 30 times shoulder slipping out of place in overhead positions
- PE: anterior apprehension, labral click, pain and weakness in maximum rotation, arm 90 deg. abducted



Bucket handle tear, labrum



Scope posterior



Anterior-inferior glenoid preparation, labral debridement



Removal unstable SLAP tissue



Mobilization of anterior-inferior capsuloligamentous complex, labral debridement

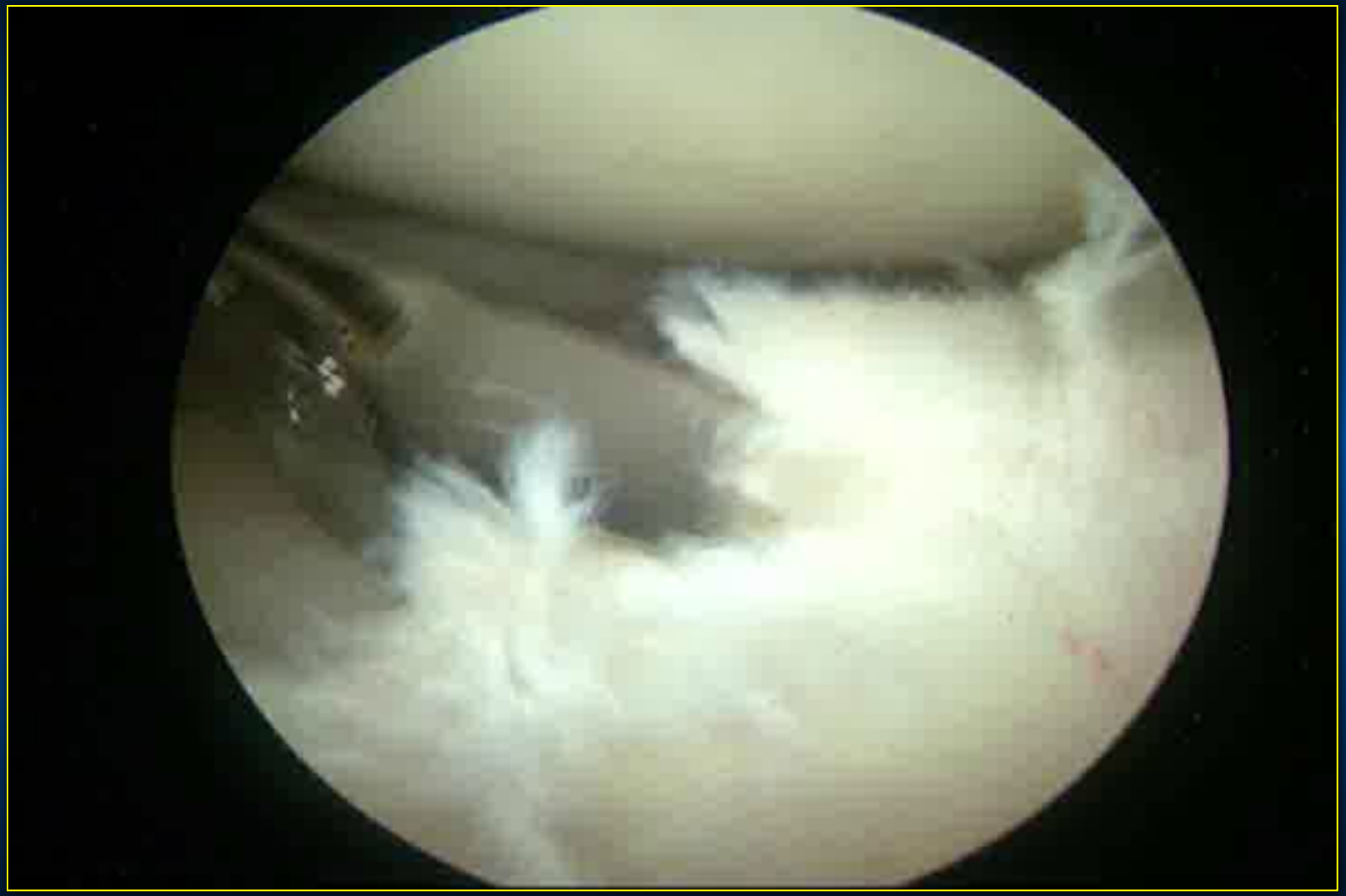



Osseous raptor x3, 6 sutures



Post-repair, arthroscope posterior



Arthroscope anterior, debridement degenerative non-repairable posterior labrum



Arthroscope anterior

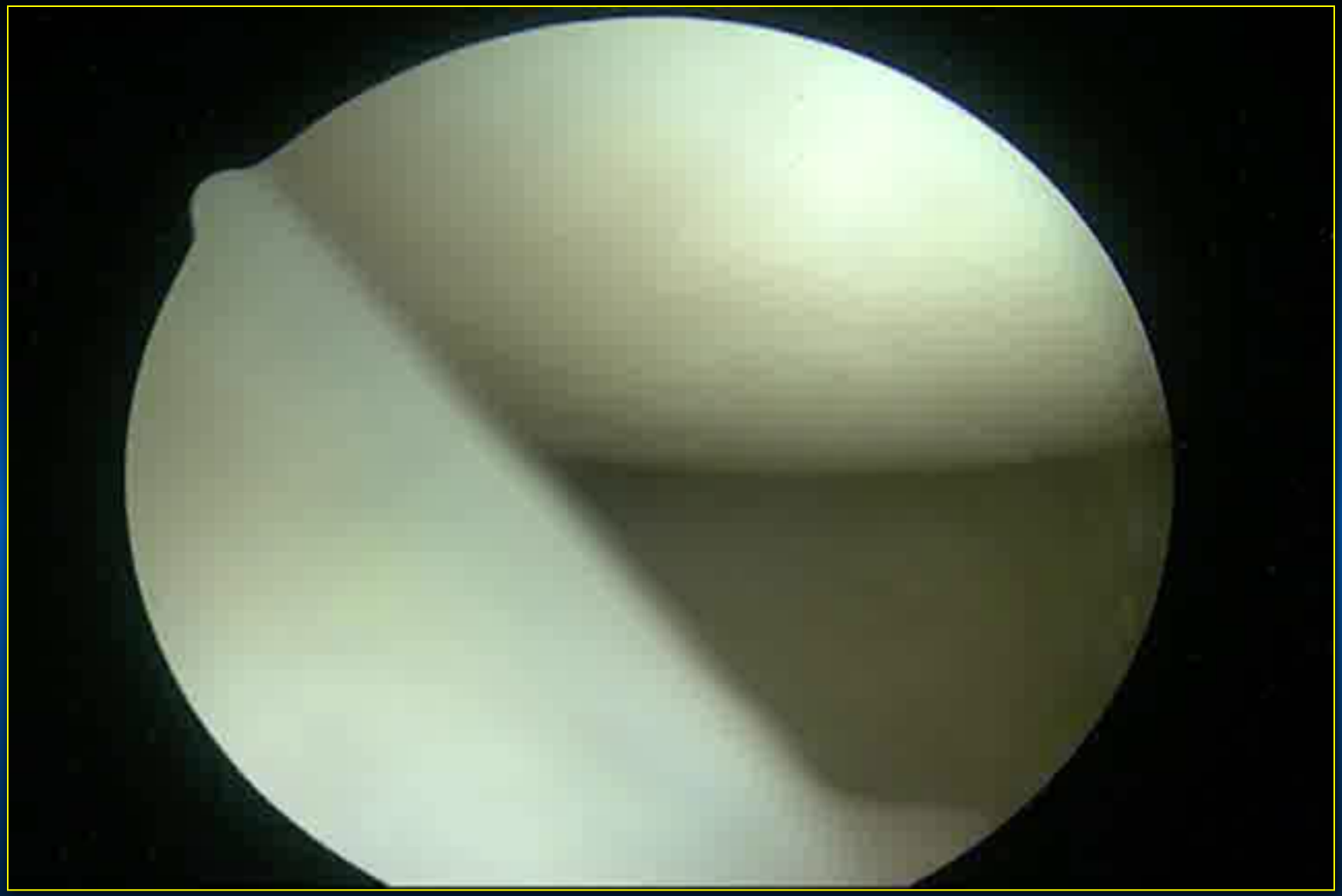

Scope anterior-superior portal, bumper stability re-established



Subscapularis bursa, common location of loose bodies
Scope anterior-superior

Case 2
Subscapularis Tear & Anterior Instability

- 49 YO Right-hand dominant white female, homemaker
- Right shoulder injury swinging basket full of clothes overhead
- PE: Significant limitation of motion
- Anterior apprehension
- Positive O'Brien's test
- Weakness, ER > IR

Imaging Studies



Scope posterior



Sublabral hole



Biceps normal, 10% upper subscapularis tear
Scope posterior

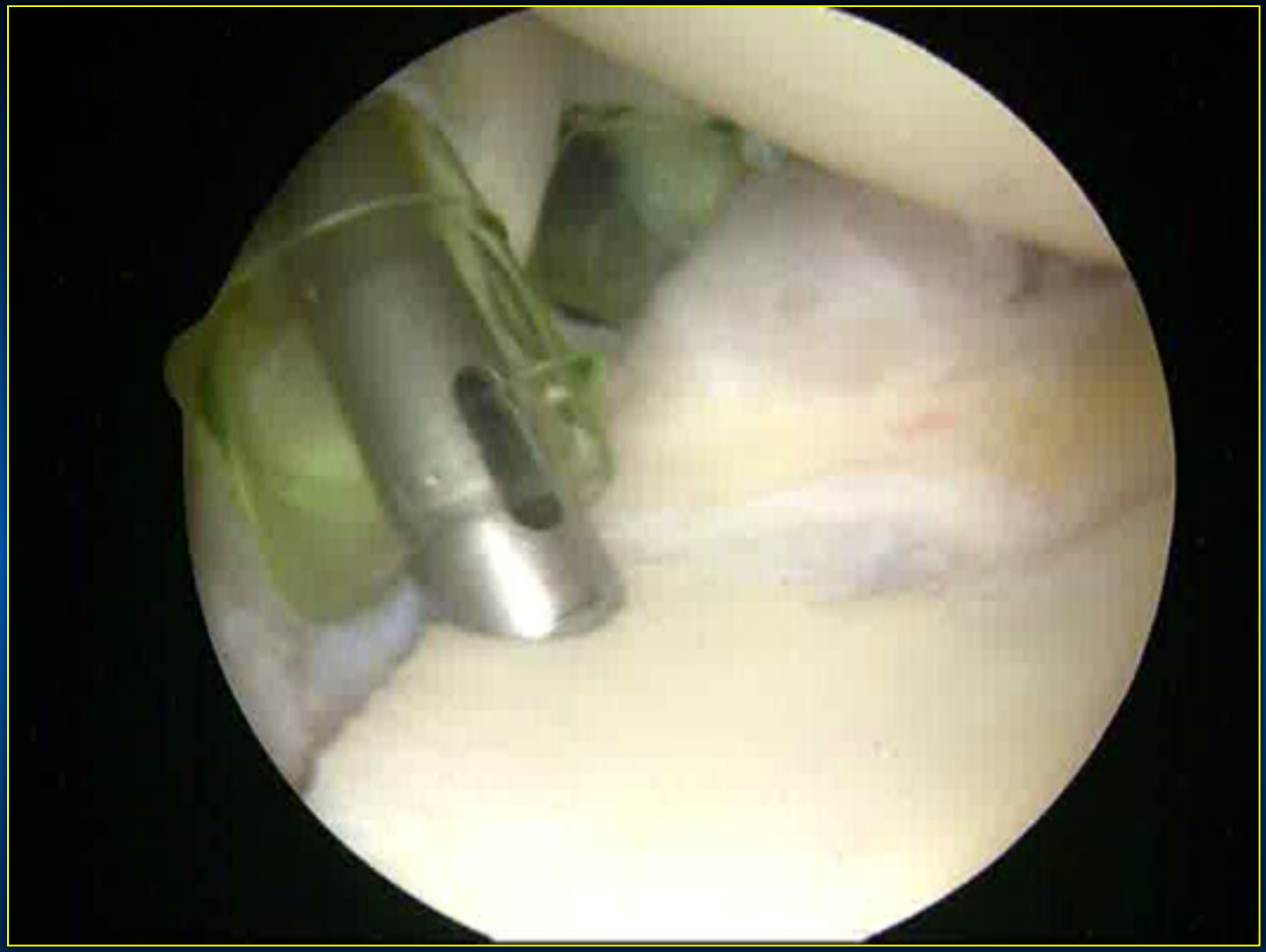

Scope posterior
Anterior-superior and anterior portals



SLAP labral repair, anchors x2, mattress sutures



Scope posterior, s/p subscap debridement

Subscapularis Muscle

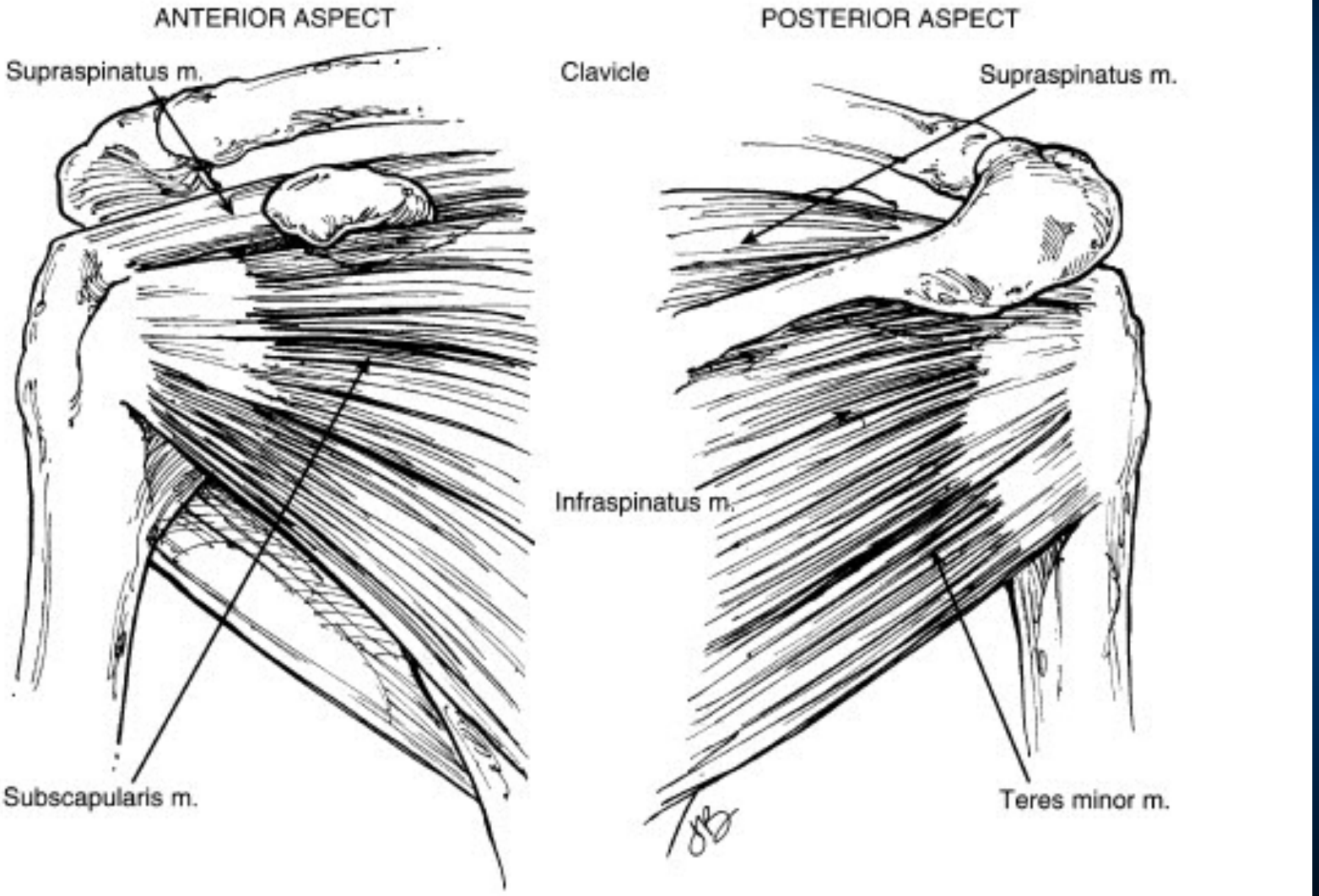

Subscapularis Tears

- Lift Off (75% tear 5-30)
  - Hand or back Lspine
  - Maximum LR
- Napoleon (50% tear)
  - Press belly, flexes wrist
- Bear Hug (Upper tear, most sensitive)
  - Hand on opposite shoulder
  - Elbow forward
  - Examiner pulls hand off shoulder

Initial Clinic Visit

- 46 year-old right-hand dominant male fell onto an outstretched right arm after tripping over his dog.
- Felt a ripping sensation in his shoulder
- Went to the emergency room, plain x-rays normal
- PE next day:
  - Pain diffusely anterior shoulder
  - Weakness, IR > ER

Clinical exam: subscapularis tear



"I was unable to get my wallet out of my back pocket."

Subscapularis & Biceps Instability

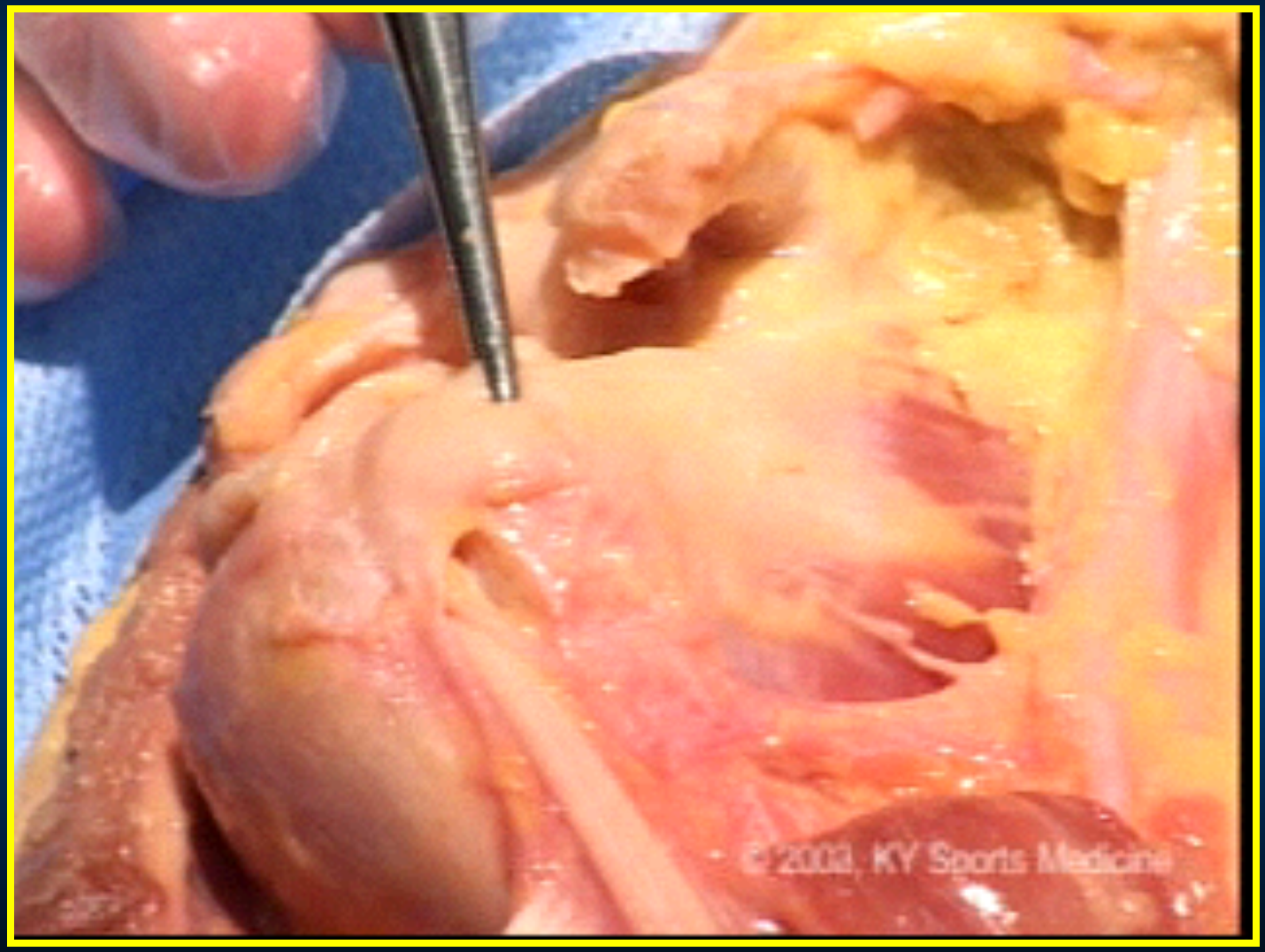

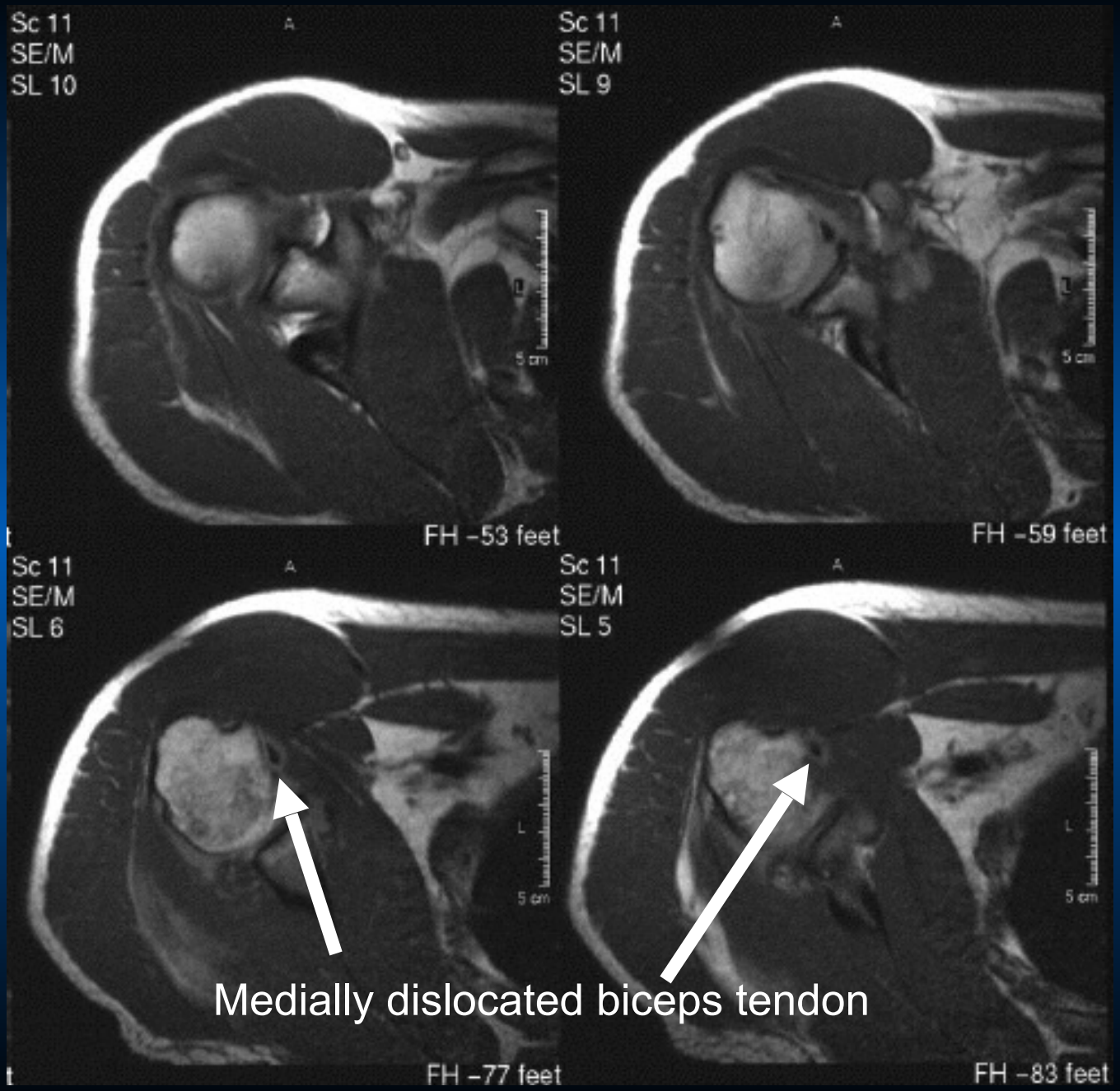
Sc 11
SE/M
SL 10
FH -53 feet
Sc 11
SE/M
SL 9
FH -59 feet
Sc 11
SE/M
SL 6
FH -77 feet
Sc 11
SE/M
SL 5
FH -83 feet
Medially dislocated biceps tendon

Subscapularis Footprint

- 2.5 cm superior-to-inferior
- 1.5 cm medial-to-lateral
- Widest superiorly

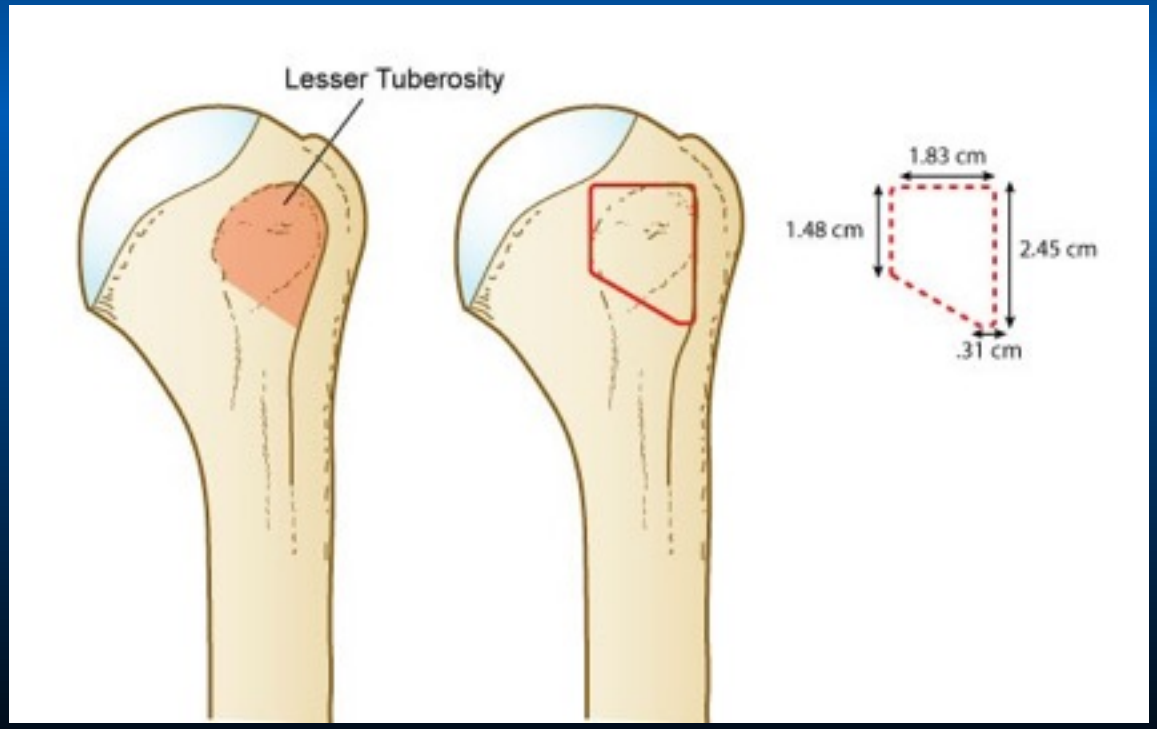



Nevada analogy by Stephen Burkhart, M.D.

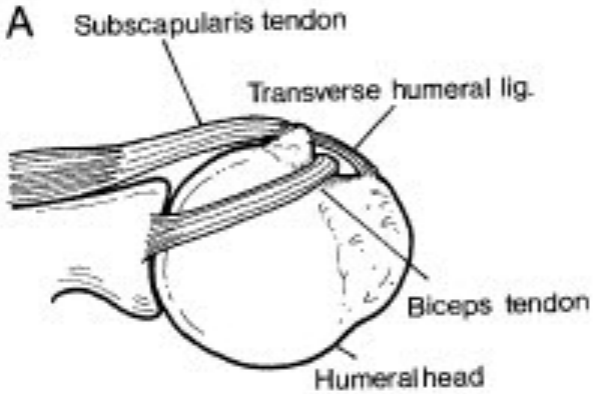

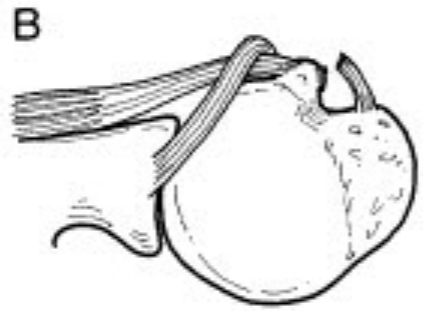



FIG 4. Superior view of right shoulder. (**A**) Normal relation of biceps tendon to bicipital groove. (**B**) Rupture of transverse humeral and coracohumeral ligaments, but no disruption of subscapularis tendon. (**C**) Tear of subscapularis tendon and coracohumeral and transverse humeral ligaments (as occasionally occurs when the humerus dislocates anteriorly. (Modified from Hitchcock HH, Bechtol CO. Observations on the role of the tendon of the long head of the biceps brachii in its causation. *J Bone Joint Surg* 1948;30A:263–273, with permission).

Bicepital Groove

Biceps Tendon

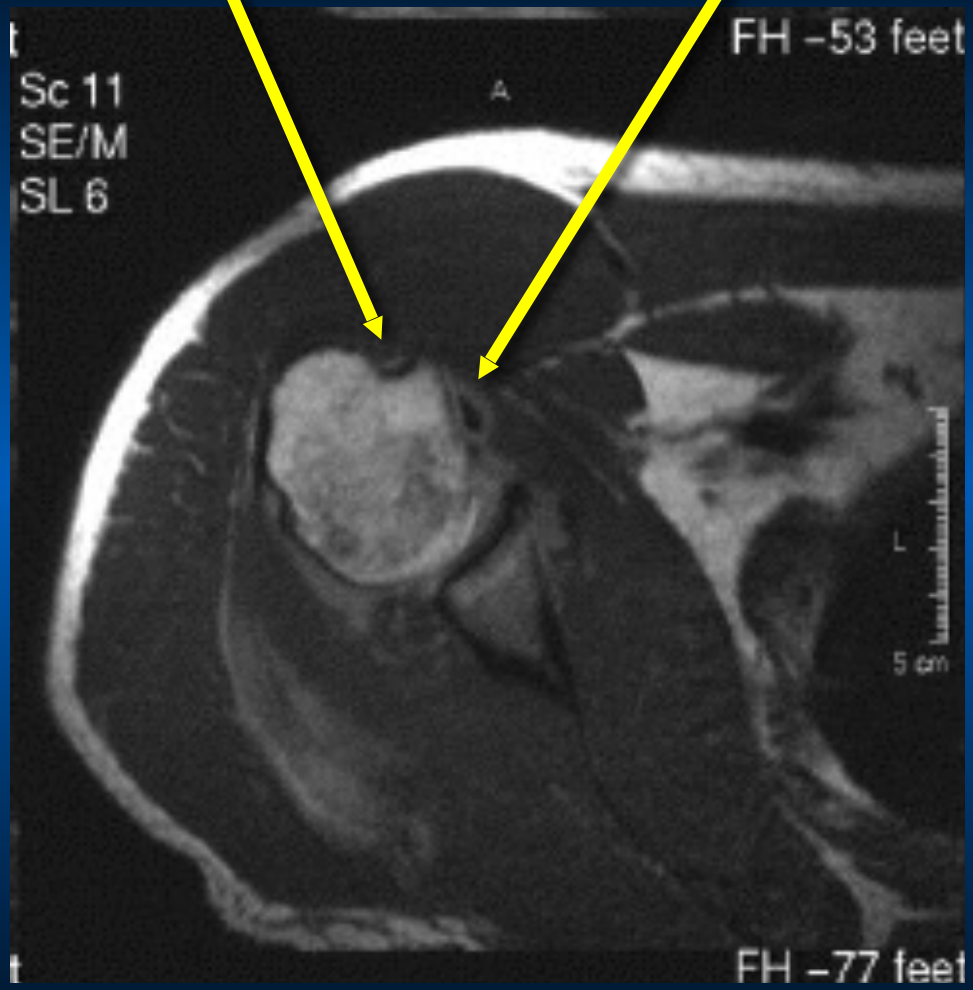

Synovitis, partial subscap tear, normal biceps tendon

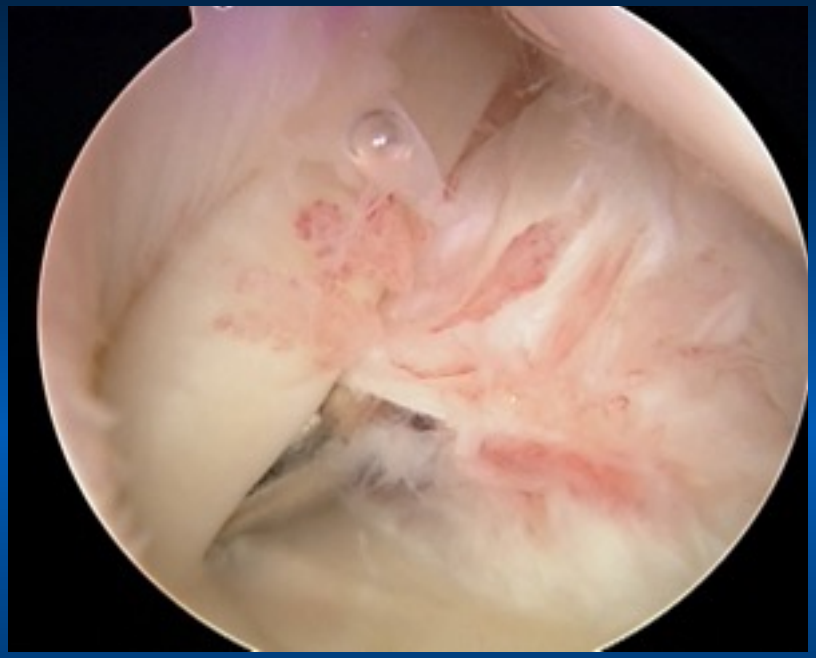

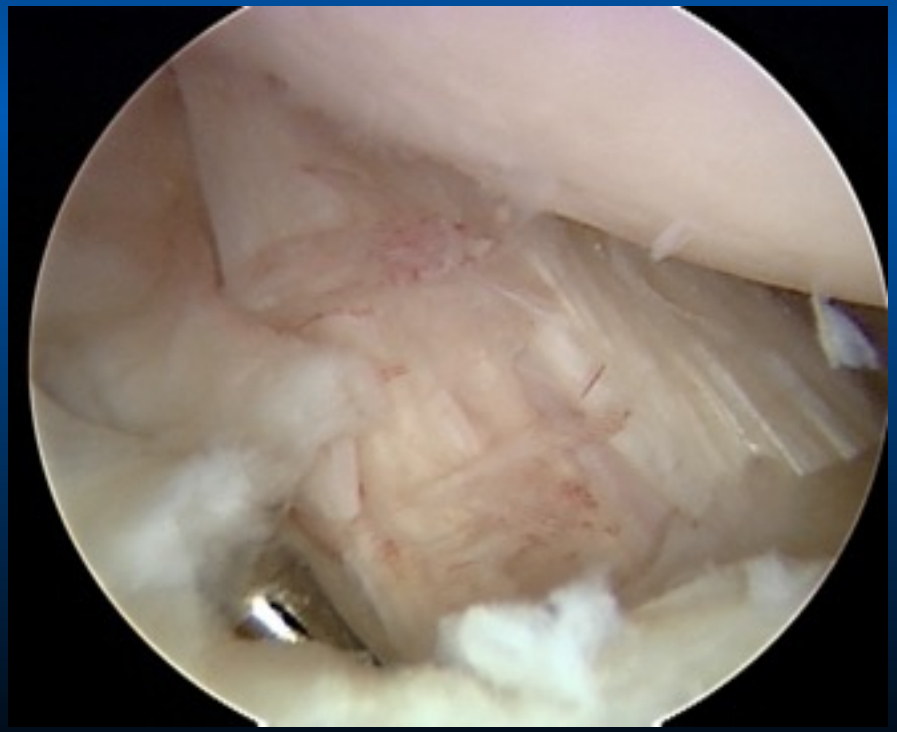

Don’t miss subscapularis tears; can be difficult to see at footprint/insertion

Biceps Tendon



- Often associated with:
  - Subscapularis tear
  - Chronic rotator cuff tears
- Presentation
  - Initial ecchymosis and pain, then feel better
- Treatment
  - Repair other associated tears
  - Tenodesis vs. tenotomy

MRI Scans of the Shoulder

- Make sure you know the type scanner and radiologist
- Communicate with radiologist regarding your clinical diagnosis
- If you can’t read the MRI scan, you shouldn’t be ordering it

MRI Scans

- I have never seen a normal reading
- It's a slippery slope to treat based on radiologists' reading



北京医科大学第三医院放射科

MRI 检查申请单

CT、MRI号_____
X 线 号_____
病 案 号_____

申请日期：00年10月12日　　检查日期：0 年 月 日

姓名	汉字：孙·爱	男、女	出生：00年10月12日28岁	体重 Kg
	拼音：	科室 运医	病房床号	电话
患者永久通讯地址			邮编	电话

请注意：装有心脏起搏器的患者以及动脉瘤术后者不能作此项检查！

由临床医师逐项填写

病历摘要：左膝关节外侧半月板切除术后半年，[illegible]

有时间痛，[illegible]

查：由[illegible]

[illegible] Lachman 时

手术史：无、有（ 年 月 日 ）

临床诊断：左膝前交叉韧带断裂，内侧副韧带部分断裂，[illegible]

检查部位与要求：左膝关节

体内金属：无、有（ ）　　申请医师 [illegible]

上海长海医院 MRI 报告单

姓名 孙爱　性别 女　年龄 28岁　科别 骨　检查部位 左膝

病区 [illegible]　床号_____　住院号_____　MRI 号 50666　报告日期 2000.10.23

左膝关节MRI

MRI 所见：

各序列扫描示左膝关节骨质略有增生，关节腔内少量积液，关节滑膜有增厚，以外后侧为最。内侧半月板后角在左旋上可见水平线状高信号，外侧半月板后角可见明显高信号线状影，与后关节束滑膜相连接，局部可见有小束状对积液。后交叉韧带连续性好，信号无异常，前交叉韧带也无特殊。两侧副韧带也无明显异常。

CONCLUSIONS

- Practice makes better, never perfect
- Practice, practice arthroscopy in the wet lab
- Practice, practice knot-tying
- Be ready to face complications in surgery

The End. . . Thank You!

